

## Breast ultrasound

Heino Hille<sup>1</sup>, Ralf Ohlinger<sup>2</sup>

<sup>1</sup> Practice for Gynecology and Obstetrics, Hamburg

<sup>2</sup> Interdisciplinary Breast Center of the University Clinic,  
Ernst Moritz Arndt University, Greifswald

Reviewers: Annette Loeck, Hamburg  
and Jens Blohmer, Berlin

### Summary

Breast ultrasound constitutes one of the settled imaging techniques of the breast besides mammography and magnetic resonance imaging (MRI). Breast ultrasound is used complementary to the other imaging modalities in early detection of breast cancer, but owns advantages in dense breasts and therefore especially in premenopausal women. Sonography of the breast could be used as a first line imaging method in women with dense breasts, if used in high quality. In symptomatic patients presenting with lumps and in following care of breast cancer patients, breast ultrasound seems to be the method of choice. New technical equipment like 3D, Sono CT, THI (“tissue harmonic imaging”), elastography are described and questioned concerning advantages in breast ultrasound.

### Introduction

Besides mammography and magnetic resonance imaging (MRI), breast ultrasound is one of the three established pillars of imaging diagnostics of the breast (Degenhardt et al. 2000; Ohlinger et al. 2002; Duda et al. 2004; Stavros 2004; Barth 2005; Fischer et al. 2005; Madjar 2005, 2008; Sohn et al. 1999, 2006). Mammography has been used the longest and studied the most, apart from also being well standardized. It is approved as a screening method for breast cancer and its use is now also established in Germany. MRI and ultrasound are more recently developed methods that have been clinically used since the 1980s. However, due to the dynamic development of technical equipment and incomplete standardization of study protocols, there has not yet been a final classification of these methods in the diagnostics of breast cancer. All present classifications of imaging methods and the description of their relationships to one another are only provisional and in a state of flux.

These three imaging techniques methods vary in sensitivity, depending on the type of glandular tissue and type of lesion examined. Mammography is most dependent on the density of the breast and tumor type, and MRI is the least dependent. Complementary or additive use of the methods is therefore most successful and precise; however, this does not mean that all methods should be employed in all cases or that this is economically viable. It is foreseeable that ultrasound and MRI will gain in importance in breast diagnostics (Hille et al. 2004; Ohlinger et al. 2006; Sehgal et al.

2006; Smith 2007), but this is not yet reflected in the guidelines (Schulz et al. 2003).

### Methodical characteristics of breast ultrasound

In contrast to the ionising radiation used in mammography, sonography is based on the reflection of acoustic waves from interfaces of varying impedance (resistance to the spread of acoustic waves) in the scanned tissue from which the B-mode is generated using an evaluation algorithm. Apart from the extent of the impedance-dependent reflection, the quality of the image also depends on other physical phenomena such as dispersion, refraction and absorption of the sound waves.

The overall image of the architecture of the breast is good in breast sonography, and it corresponds better to the real anatomy than the results of mammography, which functions by a summation technique (Figs. 1, 2).

Ultrasound imaging is therefore accompanied by the advantages and disadvantages of the reproduction of biological complexity: on the one hand, many physiological and pathological conditions are accessible to sonographic diagnostics, on the other, they are not always easy to detect and – analogous to the wide range of biological variations – sometimes the classification is unclear (decreasing specificity). Examination by ultrasound does not therefore serve as an objective complete image of the breast, but is principally rather the finding itself (dynamic and subjective character of the method), although a representative image of the lesion is available as a document for retrospective diagnosis. Due to the subjective character of the method and the associated difficulties of standardization of the procedure, ultrasound would appear to be less suitable as a sole screening method in the narrower sense (population-related screening).

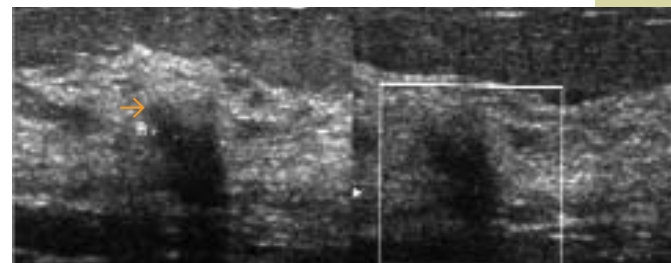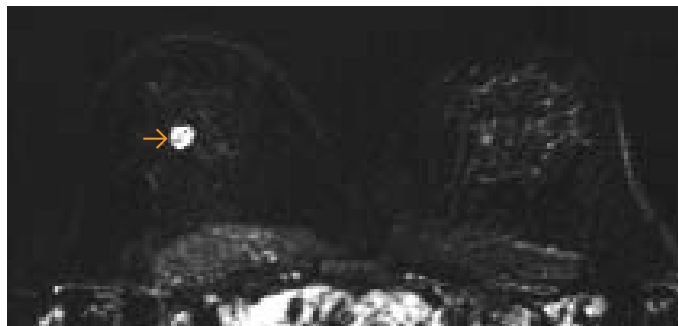
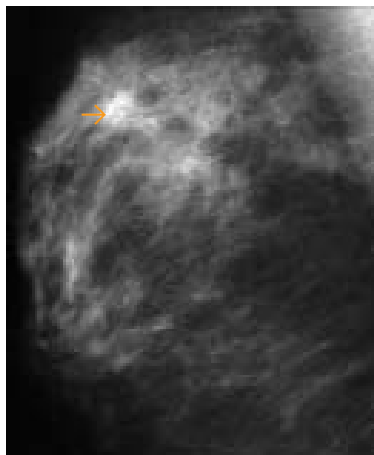
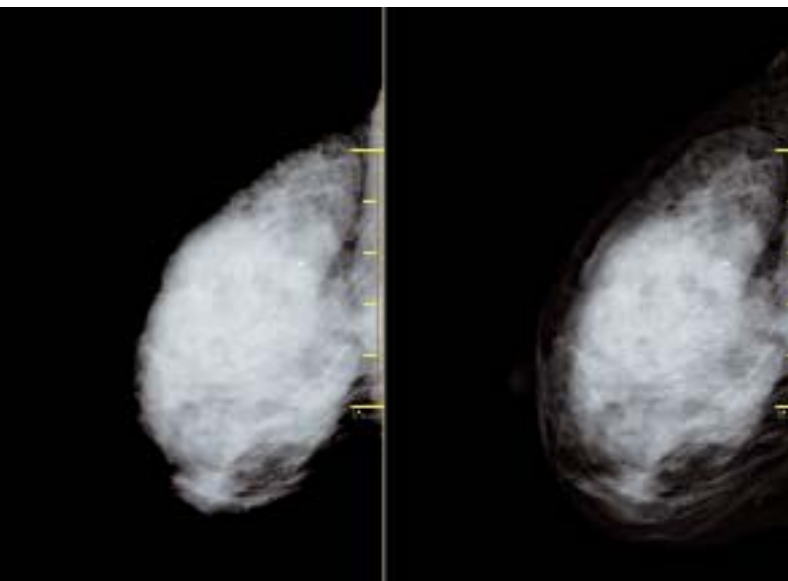

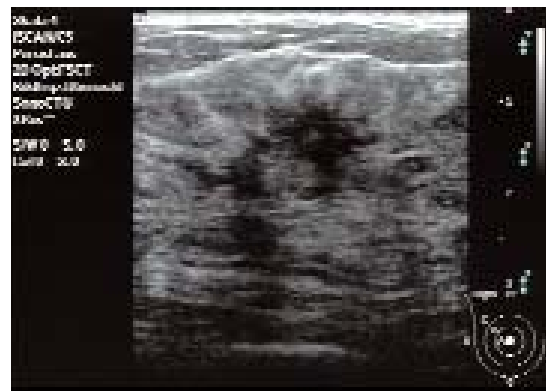
Fig. 1: Parallel images of a breast carcinoma shown using the three imaging methods

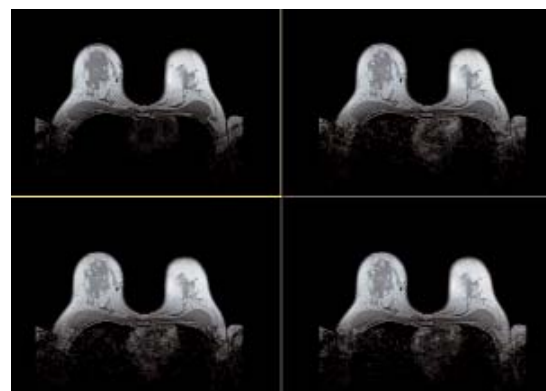
a: Mammography, b: MRI, c: Breast ultrasound



a



b



c

Fig. 2: An extensive breast carcinoma in a high density breast (ACR 4), mammographically occult (a), visible sonographically (b) and tomographically/ in MRI (c)

### Technical requirements and qualifications

It generally applies that a method is dependent on the quality of use, with respect to the user and the quality of the technical equipment. This dependency applies particularly to breast ultrasound. Only intensive and continuous training, a high frequency of examinations and equipment of a high standard can guarantee the satisfactory precision of the readings. The German Society for Senology and the German Society for Ultrasound in Medicine (DEGUM) have specified reference guidelines ([www.degum.de](http://www.degum.de); [www.senologie.org](http://www.senologie.org)). Only modern equipment upward of good middle-class standard, equipped with high frequency linear transducer probes, (on offer from leading manufacturers for 40,000 to 60,000 Euros) should be used for breast ultrasound. Broadband transducers with a bandwidth of between 5 and 15 MHz, which offer a good near-field and long-range response, are most suitable (Laqalla et al. 1998; Schulz-Wendtland et al. 2005). These transducer probes must correspond to good signal processing performance in the hardware. Nowadays, a color Doppler should be integrated, as it can provide important additional information for the characterization of breast lesions in positive or negative verification of vascularization (see below).

A 3D transducer offers advantages as it additionally images the C-mode (see below), but by today's standards it is not a constitutive module of equipment for breast ultrasound. Older equipment with 5 to 7.5 MHz probes and a coarse resolution should no longer be used for breast ultrasound, even if it still meets guidelines of medical societies.

### Performance of the examination

Sonographic examination of the breast is carried out with the patient lying down with arms elevated, and the probe is lead in a meandering, overlapping path (Fig. 3). It is recommended that the examination be carried out on two vertical planes (transverse and longitudinal) as there is the danger, especially with voluminous breasts, of incomplete examination of the breast. A radial examination technique can be alternatively or additionally used to image the central retromammillary efferent and peripheral milk ducts in the longitudinal plane (Fig. 4). Finally, the main structures of the axillae should be examined for alterations to the lymph glands.

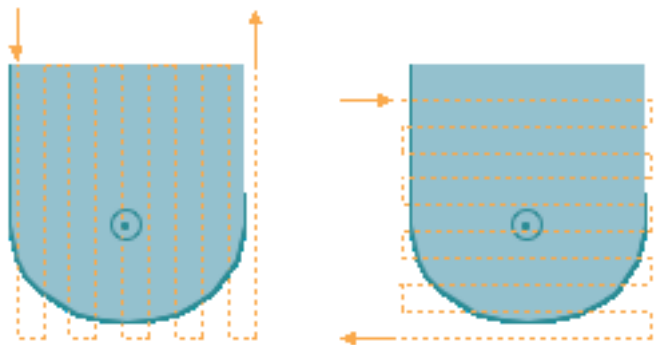


Fig. 3: Meandering path of the transducer probe on 2 planes

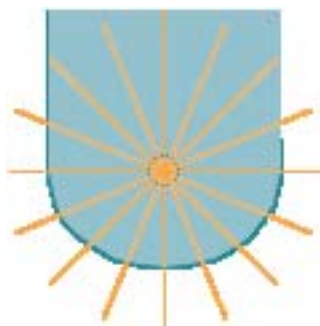


Fig. 4: Radial path of the transducer probe for imaging the efferent and milk ducts on a longitudinal plane

**Documentation**

Representative central slices of the gland architecture of each breast are documented. The image should always be marked with identification of the patient and date of the examination. The region of the slice should be noted in writing or shown graphically.

Breast sonography differentiates topographically in the whole of the slice image between skin, subcutaneous fat, the fascia of the breast, the glandular body with milk ducts, the collection and efferent ducts, the mamillae, the fat globules above and within the gland, the retroglandular fatty tissue, the dorsal fascia and muscles, as well as the breast wall and ribs (Figs. 5, 6). The individual characteristics of the glandular body itself are of particular interest regarding the relative proportional volume, the architecture of the milk ducts, and fibrous or cystic alterations.

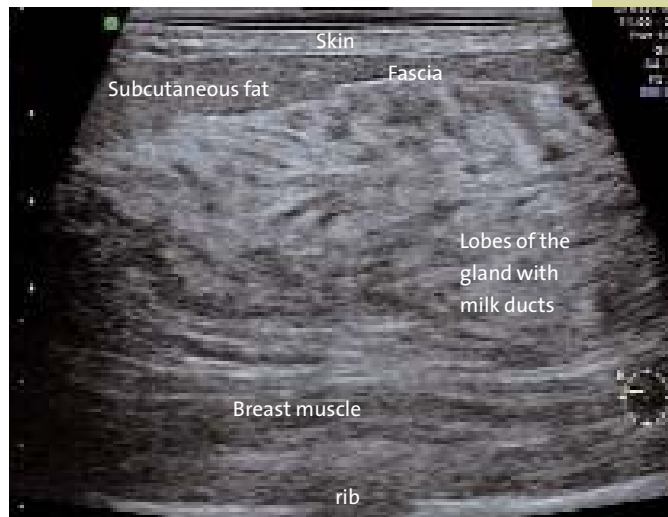

Fig. 5: Anatomy of the breast in a sonographic slice

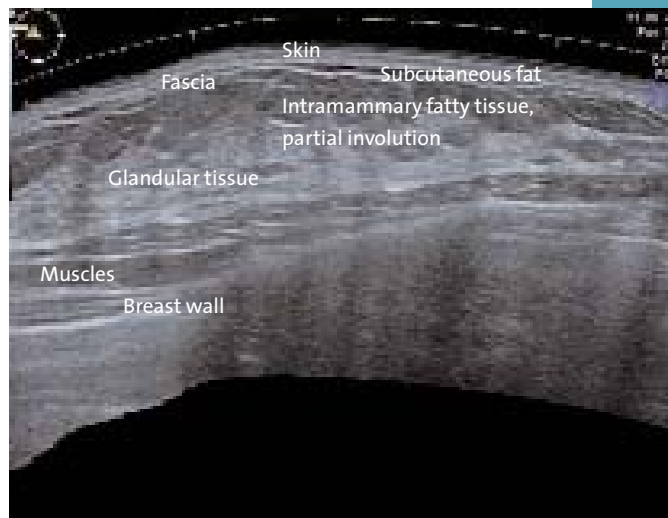


Fig. 6: Overview in XTD view

The density of the breast should be classified according to the ACR mammography standards (American College of Radiology) 1-4, depending on the relative proportion of glandular to fatty tissue in the description of the findings (ACR 2003; Madjar et al. 2006) (Tab. 1).

Table 1: Classification of breast density according to ACR

ACR	Proportion of glandular tissue (%)
1	0-24
2	25-50
3	51-75
4	76-100

**! It is important to note that the density according to ACR is exclusively the relative proportion of glandular tissue to fatty tissue in the individual breast, and not the echogenicity of the sonographically imaged glandular tissue itself. !**

A breast which is composed almost completely of glandular tissue during pregnancy, but which sometimes presents isodense to fatty tissue, would be correspondingly classified as ACR 4; a breast with about 50 % fibrous echo-genic glandular body would on the other hand be classified as ACR 2 (Figs. 7, 8).

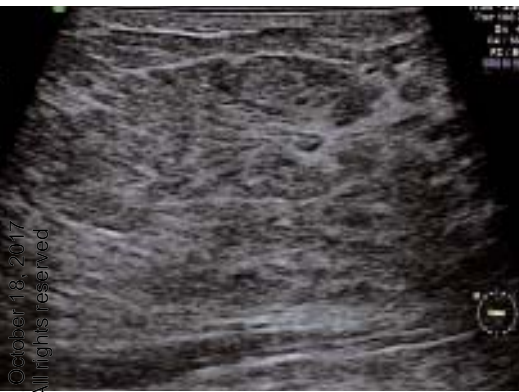


Fig. 7: Almost isodense glandular tissue during pregnancy: density ACR 4

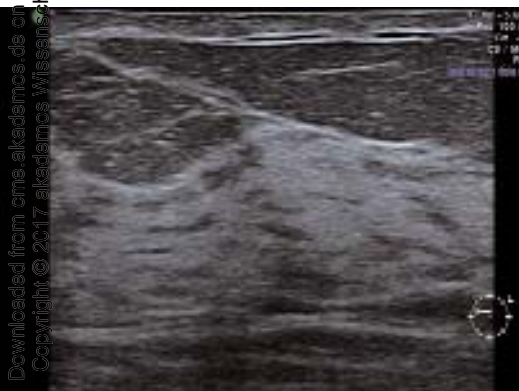


Fig. 8: Moderately fibrous glandular tissue, about a 50 % proportion: density ACR 2

The description of the sonographic echogenicity of the glandular tissue is relevant, however, as it characterizes the individual architecture of the gland. The final reading should contain a classification of malignancy analogous to the BI-RADS (Breast Imaging and Reporting Data System) categories 1-5 (ACR 2003; Madjar et al. 2006) (Tab. 2).

Table 2: Malignancy criteria

BI-RADS 0	Incomplete, needs additional evaluation
BI-RADS 1	Findings normal
BI-RADS 2	Benign findings
BI-RADS 3	Probably benign (short-term monitoring recommended, possible puncture or core needle biopsy)
BI-RADS 4	Suspicious, (core needle) biopsy recommended
BI-RADS 5	Malignant, histological examination required

The reading should include a recommendation for further procedure.

### Sonographic detection of lesions

In the case of lesional findings, imaging on two orthogonal planes with measurement on three axes is standard. Specification of the location is important (Fig. 9). The distance from the surface of the skin and to the mamilla is also measured and recorded. The tumor criteria are presented in Table 3.

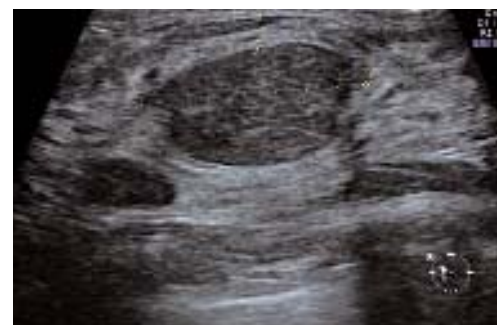
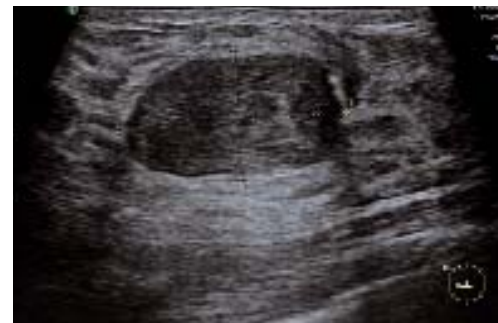
Fig. 9: Documentation of lesional findings (here fibro-adenoma) of 2 orthogonal, measurement of 3 axes and distance from the skin





Table 3: Tumor criteria (from Madjar et al. 2006)

<b>Localization</b>	Side, clock-face position, distance from mammilla and surface of the skin
<b>Tumor size</b>	Three axes, including the maximum diameter
<b>Form</b>	Round, oval, irregular
<b>Axis</b>	Horizontal, vertical, indifferent (round), not measurable
<b>Border</b>	Smooth, lobed, microlobular, diffuse, angular, spiculate
<b>Echogenic margin (halo)</b>	Present, not present
<b>Echogenicity</b>	Echo-free, hypoechoic, isodens, hyperechoic, complex
<b>Wave transmission</b>	Acoustic shadowing, indifferent, enhanced, and mixed
<b>Calcification</b>	Macrocalcification (> 0.5 mm), microcalcifications, outside the lesion, within the lesion
<b>Compressibility<sup>1</sup></b>	Good, low, non-relocatable, non-assessable (in addition to ACR)
<b>Relocatability<sup>1</sup></b>	Good, low, not compressible, non-assessable (in addition to ACR)
<b>Alterations in surrounding tissue</b>	Cooper ligaments (displaced, interrupted), edema of the tissue, edema of the skin, irregularities of the skin, disruption of the architecture, infiltration of the wall of the thorax
<b>3D criteria<sup>1</sup></b>	Compression pattern, retraction pattern (in addition to ACR)
<b>Special cases</b>	Cluster-like microcysts, complicated cysts, skin lesions, foreign bodies, intramammary lymph nodes
<b>Circulation<sup>1</sup></b>	Not examined, no vessels, vessels in TU, in the tumor borders, in the surrounding tissue Quantity (of vessels): increased, slightly increased, not increased/number of vessels Pattern of vessels; radial, tangential, irregular
<b>Further additions to ACR Lymph nodes</b>	Region: Axilla, infraclavicular, supraclavicular, neck, parasternal Evaluation: unsuspecting, suspicious
<b>Milk ducts</b>	Normal, expanded, smooth, irregular (caliber leaps), interruption of duct Interior structure: echo-free, solid, duct diameter

<sup>1</sup>Note: The dynamic criteria of compressibility and relocatability are not recognizable in the static image and must be directly recorded during the examination. 3D criteria are only applicable if with the corresponding technical equipment is used and they are not an essential part of the examination. The measurement of circulation is facultative and can be omitted in the case of cysts, in so far as there is no evidence of suspected proliferative structures

Lesions are differentiated according to their form, borders, echogenicity and the reaction of their surroundings (Stavros et al. 1995; Blohmer et al. 1995; ACR 2003; Ohlinger et al. 2004; Fischer D et al. 2006; Madjar et al. 2006). The typical characteristics of benign and malignant alterations are listed in Table 4.

Table 4: Typical characteristics for the differentiation of benign and malignant lesions (from Madjar et al. 2006, licensed)

	Benign	Malignant
<b>Form</b>	Round, oval 	Irregular 
<b>Axis</b>	Horizontal	Vertical
<b>Border (see also Fig. 10)</b>	Smooth, lobed, narrow margin (pseudo-capsule)	Lobular, angular, spiculate, echogenic (surroundings)
<b>Echogenicity</b>	Echo-free, isodens, parenchyma-like	Hypoechoic (and) inhomogeneous
<b>Wave transmission</b>	Acoustic enhancement, bilateral acoustic shadow	"Acoustic shadow"
	Relocatability and compressibility are additional dynamic criteria of benignity	Interruption of architecture is typical of malignancy, i. e. the structure of the parenchyma, in particular the Cooper ligaments become diffusely interrupted in their course (no displacement!) (see Fig. 17–20) Additional dynamic criteria are non-relocatability and lack of compressibility.

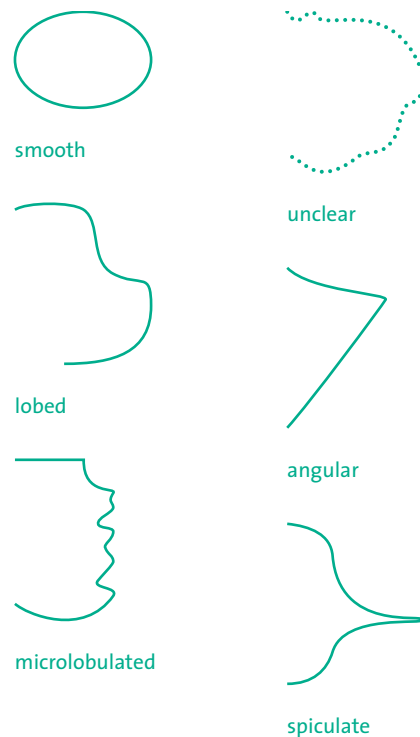


Fig. 10: Description of margin contours of lesional findings (from Madjar et al. 2006, licensed)

### Sonography as the method of choice in symptomatic patients

Sonography is the leading method in diagnostics of symptomatic alterations of the breast (Georgian-Smith et al. 2000; Houssami et al. 2003) (Fig. 11). It is not only possible to precisely recognize diffuse benign (fibrocystic, mastopathic) alterations of the parenchyma with the aid of sonography, but also benign lesions, most of which can be conclusively categorized. Some typical examples, such as cysts, fibroadenoma, and mastitis are shown in Figures 12-15. Tissue alterations which are clearly cystic are classified in the "definitely benign" category BI-RADS 2.

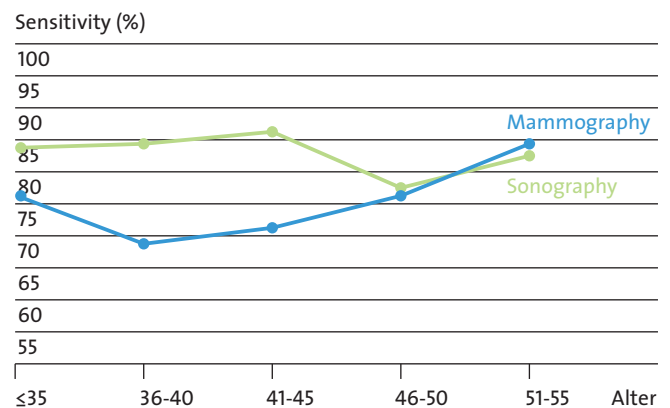


Fig. 11: Sensitivity of mammography and sonography in a symptomatic patient (according to Houssami et al. 2003)

Downloaded from cme.akademos.de on Wednesday, October 18, 2017  
Copyright © 2017 akademos Wissenschaftsverlag. All rights reserved.

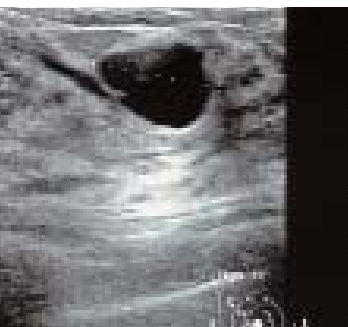


Fig. 12: Echo-free, smooth-margined lesion, acoustic enhancement: simple cysts, BI-RADS 2

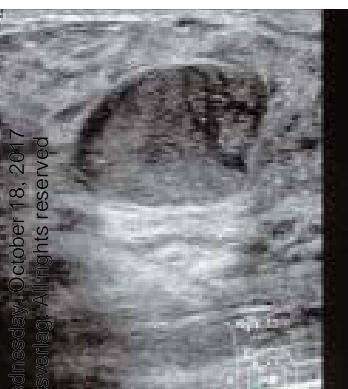

Fig. 13: Smooth-margined, not quite homogeneous echogenic lesion with displacement margin, (pseudo-capsule), acoustic enhancement. Suspected fibroadenoma: on first diagnosis BI-RADS 3; after monitoring showed no major alteration: BI-RADS 2

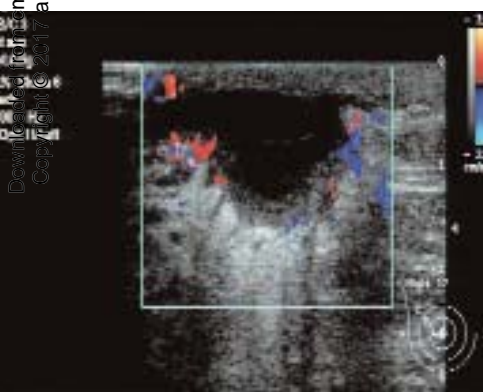
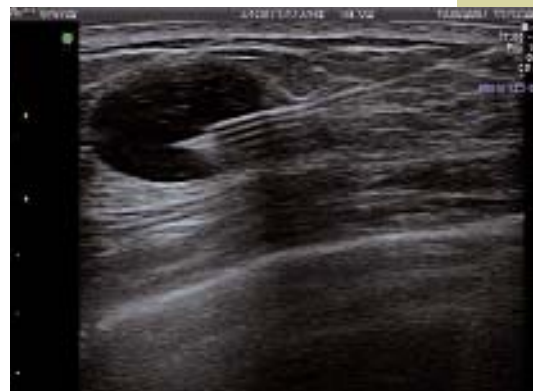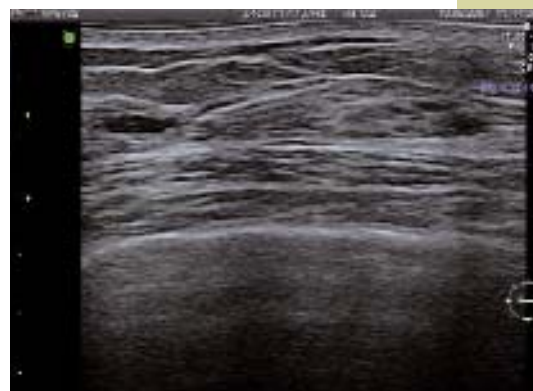


Fig. 14: Puerperal mastitis with abscess: inflammatory hypervascularization in the area surrounding the abscess



a



b

Fig. 15: Cyst puncture (a); after puncture (b)

Solid lesions with benign characteristics are assigned to Group 3 (BI-RADS 3) on first diagnosis, probably benign, as special types of carcinoma (e. g. mucinous and medullar carcinoma) can imitate benign findings. Only after negligible progression (under 20 % per year) has been verified and there has been no alteration in the sonographic structure of solid lesions during monitoring, are such lesions deferred back into Group 2 (BI-RADS 2). After six months at the latest, monitoring should take place for two years.

In the case of solid lesions which cannot be proved benign beyond doubt, the patient should be offered the option of a core needle biopsy to clarify the diagnosis. The classification BI-RADS 3 expresses a 98 % probability that the lesion is benign (Fischer U et al. 2006). However, this high probability of benignity in BI-RADS 3 findings is not confirmed by all more recent studies (Holtfreter et al. 2006; in contrast, Graf et al. 2007). On account of this, a histological back-up should be offered for medical-legal reasons, even the procedure is different within the framework of mammography screenings (the patient recalled to clarify only BI-RADS 4 and 5 findings). In cases of patients with bothersome, probably benign lesions of up to 2 cm in size, an ultrasound guided vacuum biopsy can be offered as a diagnostic and therapeutic solution (Krainick-Strobel et al. 2005).

Downloaded from me.akademios.de on Wednesday, October 18, 2017  
Copyright © 2017 Akademios Wissenschaftsverlag. All rights reserved.



Cysts which cause more serious discomfort can be punctured with a fine needle (FNA) for drainage (see Fig. 15). Open biopsy should be carried out on cysts with interior proliferations of questionable malignancy as it is possible that they can no longer be located after puncture. Ultrasound puncture is the first – also therapeutic – method of choice in mastitis accompanied by abscesses (see Fig. 14) (Rageth et al. 2004; Christensen et al. 2005), whereby a large-caliber needle should be used, such as the trocar of a 14G core needle. If in individual cases a punctured abscess does not heal after administration of antibiotics, open operative resection of the abscess is necessary. If lesions have to be localized sonographically, puncture techniques should only be carried out with the use of ultrasound guidance (Dillon et al. 2005; Wu et al. 2006).

All the above-mentioned patterns of breast lesions are not strictly specific, but are characteristics of varying probabilities of benignity and malignancy. Each finding must therefore also be individually analyzed, not purely schematically. The more applicable malignant characteristics in Table 5 are, the clearer the classification of the finding in BI-RADS 5 (Figs. 16-19). If benign and malignant characteristics are found simultaneously, the finding is categorized as BI-RADS 4 (Figs. 20-22). The analysis of the marginal structures and the reaction of the surrounding tissue are the most important criteria (Marquet et al. 2002; Chen et al. 2004; Ohlinger et al. 2004). The tumor axis criterion is of restricted importance; DCIS grow frequently, invasive early lesions are not seldom horizontal (Hille et al. 2007) (Figs. 18-20).

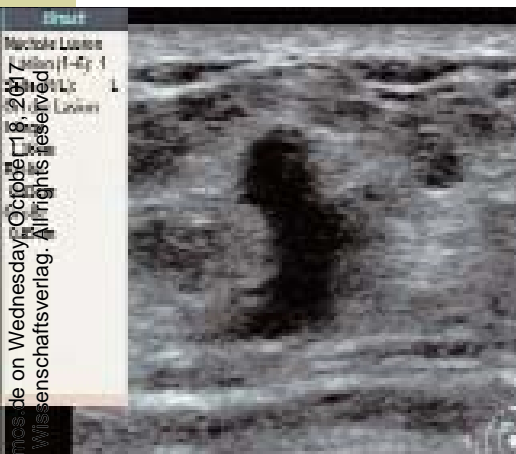

Fig. 16: Hypoechoic, irregular, angular delineated lesion, vertical axis, interruption of structure: BI-RADS 5; histology: invasive ductal breast carcinoma

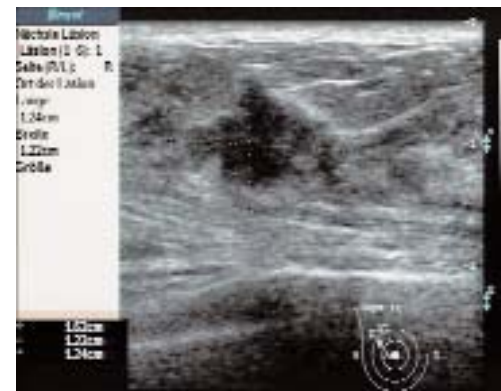

Fig. 18: Hypoechoic, diffuse, irregular lesion, structure interruption, greatest dimension: BI-RADS 5; histology: invasive ductal breast carcinoma

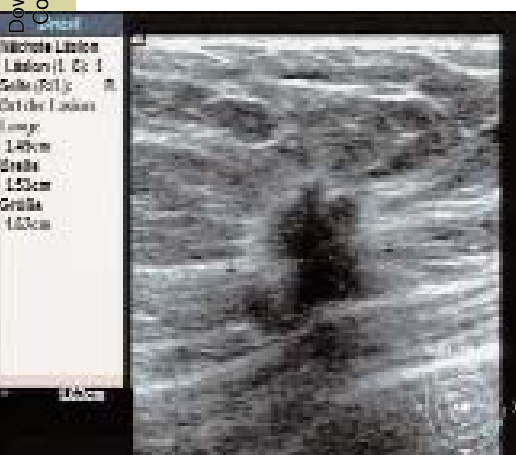

Fig. 17: Hypoechoic, irregularly delineated lesion, angular, spiculated, vertical axis, desmoplastic reaction in surrounding tissue: BI-RADS 5; histology: invasive ductal breast carcinoma

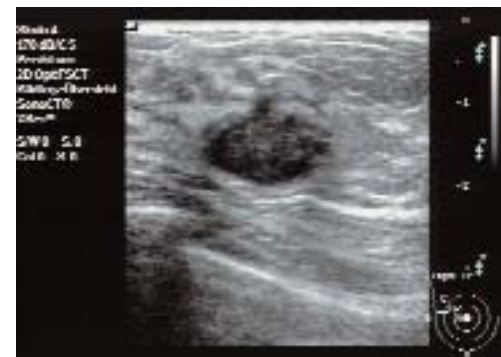

Fig. 19: Not smooth on all sides, delineation unclear, hypoechoic, inhomogeneous lesion, microlobulated, horizontal axis: BI-RADS 4; histology: invasive ductal breast carcinoma

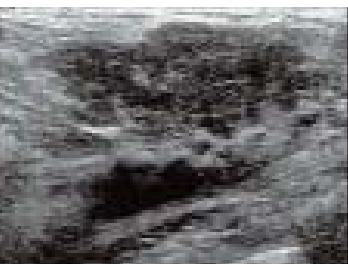

Fig. 20: Extensive, hypoechoic lesion, horizontal, microlobulated, centrally grouped echogenic spots: BI-RADS 4; histology: DCIS

### The importance of breast ultrasound as a method of early diagnosis for breast cancer

Nowadays, lesions of 3-5 mm upwards (tumor stadium T1a) can be detected with the aid of high quality ultrasound. Breast ultrasound is therefore suitable for the early detection of breast cancer (see Figs. 21, 22).

In contrast to mammography, the sensitivity of breast ultrasound is widely independent from the individual type of density of the breast. Ultrasound is therefore particularly relevant in the diagnosis of occult carcinomas in mammographically dense breasts, which are not infrequent. The increase in diagnosed carcinoma could be 30 % or more in clientele with X-ray dense breasts (Kolb et al. 2002; Leconte et al. 2003; Crystal et al. 2003; Greene et al. 2006). In a non-selected clientele with mixed breast density the proportion of diagnosed carcinoma is 15-22 %, in addition to those diagnosed by mammography (Chan et al. 2007; Buchberger et al. 2000) (Fig. 23).

Due to the limitations in X-ray prescription regulations on the one hand, (there is by law no preventative X-ray examination outside mammography), and the high percental rate of dense breasts in premenopausal women on the other, sonography is indicated here as the primary preferred imaging procedure for early diagnosis of breast cancer (Klug et al. 2004; Di Nubila et al. 2006; Greene et al. 2006; Ohlinger et al. 2006; Ohta et al. 2007; Osaka et al. 2007).

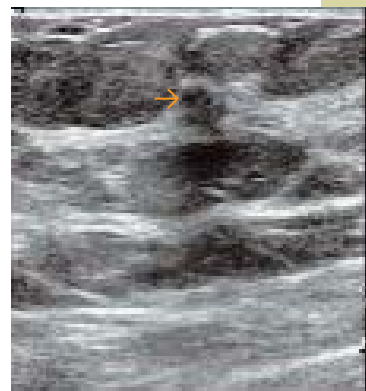


Fig. 21: 6 mm, hypoechoic, diffuse, irregular lesion (mammographically occult): BI-RADS 4; histology: lobular carcinoma of the breast

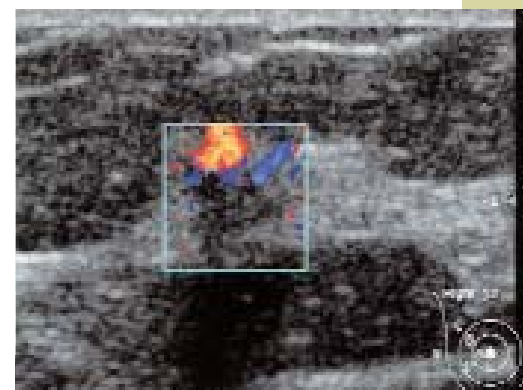


Fig. 22: Findings from Fig. 21 in color Doppler: distinct flow signals

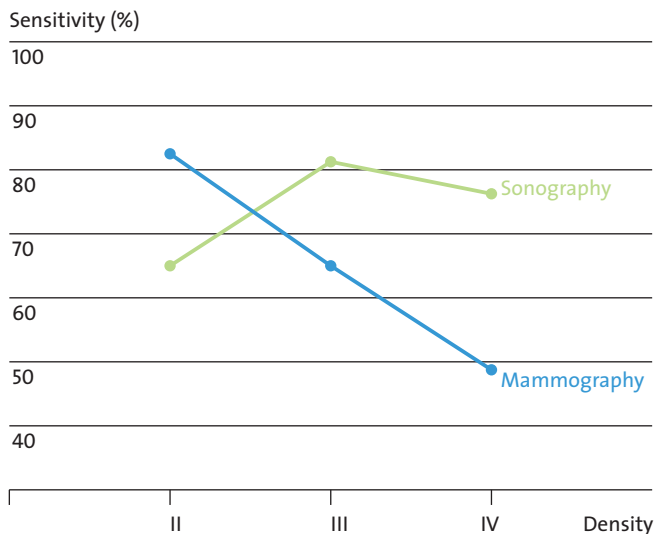


Fig. 23: Sensitivity of mammography and breast sonography dependent on breast density according to ACR category (according to Kolb et al. 2002)

Women over 50 years of age with a breast density of ACR 2-4, who take part in mammography screening, should also be offered the possibility of complementary sonography, due to the danger of mammographically occult carcinomas.

Ultrasound is particularly important (besides MRI and mammography) in early diagnosis in high-risk patients (high familial risk or BRCA mutation carrier). Breast sonography should be carried out every six months from the age of 25 onwards, or even earlier, from the age of 18 onwards (consensus paper from AGO, ÖGS, ÖGGG 2007, see References).

### Breast sonography in post-treatment care

According to the guidelines of post-treatment care, mammography should initially be used for imaging every six months (German Cancer Society 2004). Ultrasound is classified as facultative. More recent studies have shown, however, that ultrasound should be the preferred imaging method in post-treatment care (Riebe et al. 2007). Ultrasound has the advantage that it can be directly included in after-care monitoring to clarify questionable palpatory findings of the axillae and wall of the breast after ablation and examination status post breast reconstruction (Figs. 24-25). The latest results of a consensus meeting (AGO, ÖGS, ÖGGG) recommend ultrasound as a regular annual method of post-treatment care (Consensus Paper 2007, see References).

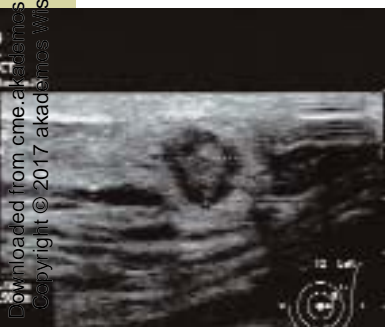


Fig. 24: Local recurrence of an invasive ductal carcinoma close to the wall of the breast after BPT

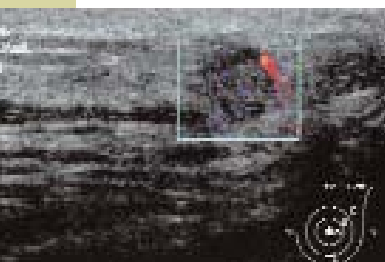


Fig. 25: Findings of Fig. 24 in color Doppler

### Limitations of early diagnosis of breast cancer by ultrasound

So far, there is only limited sonographic diagnostic access to precancerous stages such as DCIS. In mammography the typical characteristic of DCIS is the appearance of microcalcifications in a particular form and arrangement. In hypoechoic surroundings sonography images grouped echogenic spots as the correlate of mammographical microcalcifications (no 1:1 figure) (see Figs. 20, 26). In echogenic surroundings, however, and so far as there are no other lesional findings, the intraductal precancerous stages evade detection in sonography. However, when MRI is used, it becomes apparent that the proportion of DCIS that do not present any microcalcifications is relatively high (Kuhl et al. 2007). Sonography can be of relevance in the future regarding these forms, when the special characteristics of DCIS, as distinguished from the invasive lesion, come more into focus (fat-like isodens, lack of acoustic shadowing, horizontal tumor axis, microlobulation, see Figs. 20, 26, 42) (Hille et al. 2007). This requires a more precise analysis of the architecture of the breast including the milk ducts, not simply a search for classical lesional findings.

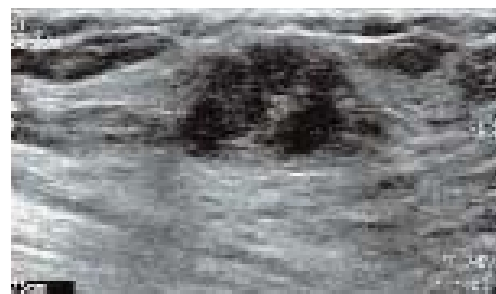

Fig. 26: Hypoechoic, inhomogeneous, microlobular lesion with groups of microcalcifications, horizontal axis: BI-RADS 4; histology: DCIS

Very dense, but echo-inhomogeneous breast architecture cannot be evaluated conclusively by sonography. Invasive carcinoma can “hide” in strongly inhomogeneous and/or wave attenuating parenchyma. DCIS cannot be defined or sonographically precluded (Figs. 27-28). The category BI-RADS o (evaluation insufficient, further imaging diagnostics required) should also be applied in this case.

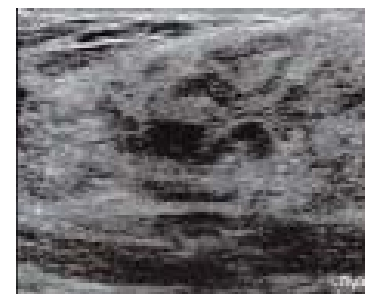

Fig. 27: Echo-inhomogeneous glandular architecture in fibrocystic mastopathy with extended, irregular milk ducts paths: BI-RADS o

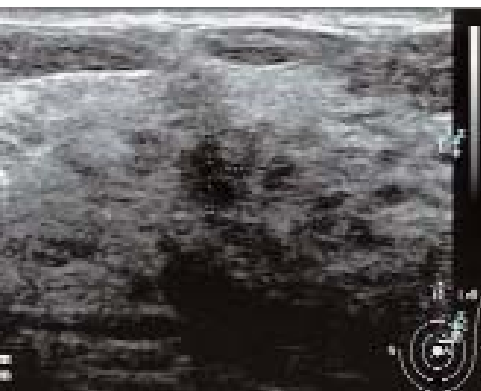

Fig. 28: Strongly signal-weakening, sonographically dense glandular parenchyma with no possibility of definitive evaluation: BI-RADS 0; Mammographic: suspected extensive DCIS; Histology: extensive DCIS with invasive lesions

### Additional technological modules in breast ultrasound

#### Color Doppler (CFM)

Malign tumors induce angiogenesis in order to make their uncontrolled growth possible. The CFM (and also non-direct power Doppler) can be used to color code erythrocyte movement in tumor vascularization. The CFM is therefore used for further examination of lesions. Differentiation is made between evidence of vascularization or non-vascularization. In positive findings the pattern of circulation is described (Madjar et al. 1994; Lee et al 1996; Blohmer et al. 1999; Schelling et al. 1997; Peters-Engel et al. 1999; Lee et al. 2002; de Cura et al. 2005; Weismann 2006). Vessels in marginal areas of lesions are more likely to be non-suspect (Strano et al. 2004), whereas vessels with a radial pathway and vessels with higher and varying speeds, also spiral vessel pathways, are typical of malignoma (Figs. 29-31). Aggressive, highly malignant carcinoma show earlier and more distinct flow signals. Evidence or the lack of color-coded flow signals is, on its own, not a definitive (specific) characteristic (Lee et al. 1996; Watermann et al. 2004). For example, there may be no sonographically detectable flow signals in malignant lesions, but they may, on the other hand, be found in benign findings (e. g. myxoid fibroadenoma, lactating adenoma) (Figs. 32, 33). Conversely, benign findings in the B-mode give rather more cause for suspicion, and histology should be performed as a safeguard when they are noticeably well perfused (Figs. 34, 35). Use in the latter situation is one of the most important functions of the CFM. It is not the additional confirmation of the suspect findings in B-mode, but the deferment of lesions found in the B-mode image, which are more likely to be categorized as BI-RADS 3, into the category BI-RADS 4, due to evidence of vascularization with the need of further clarification.

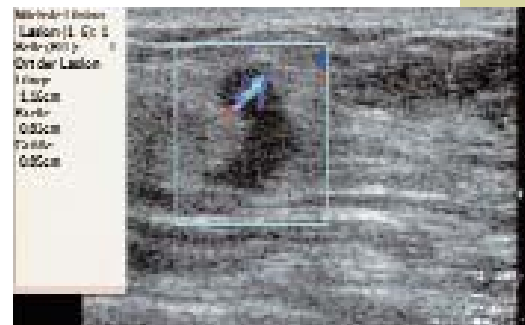


Fig. 29: Finding from Fig. 16 in color Doppler: suspect vascularization with a radial pathway into the lesion

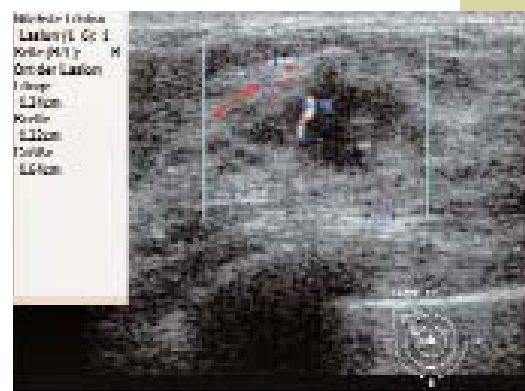


Fig. 30: Finding from Fig. 18 in color Doppler: suspect, central vessel in the tumor

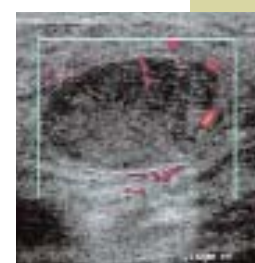

Fig. 31: Vessel pathway in the capsule of a fibroadenoma; only discrete intratumoral vascularization

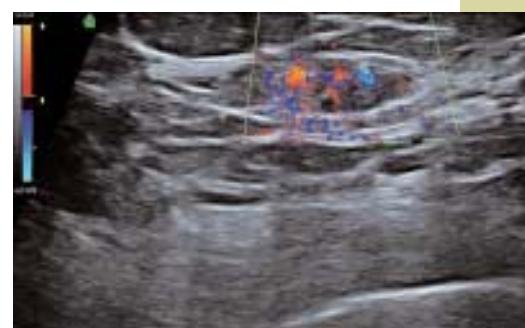

Fig. 32: Lesion with smooth margins, noticeably increased intratumoral vascularization; ranking increased from BI-RADS 3 to BI-RADS 4; histology: "complex (myxoid) fibroadenoma"

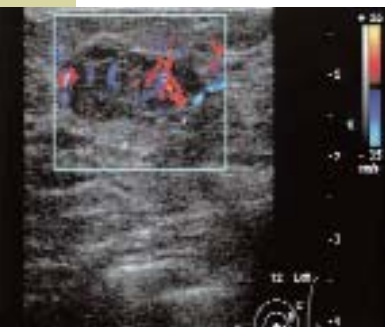

Fig. 33: Strongly vascularized, smooth bordered tumor in pregnancy: lactating adenoma

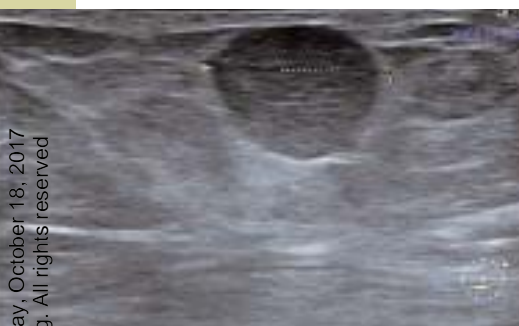


Fig. 34: Smooth bordered, hypoechoic homogeneous tumor; suspected protein-containing cyst or fibroadenoma

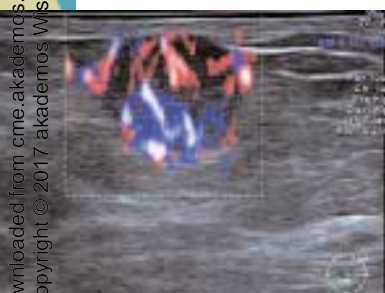
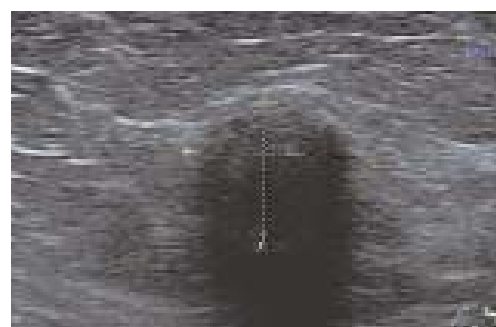
Fig. 35: Finding from Fig. 34 in color Doppler: very strong hypervascularization; ranking increased to BI-RADS 4; histology: adenopapillary breast carcinoma



a



b

The use of the spectral Doppler for measuring resistance indices is not established in breast sonography as standardization of quantification is difficult, due to very varying flow speeds in the vessels within the tumor and to an often meandering pathway. High speeds of flow ( $> 20$  cm/s) and high resistance indices can be indications of malignancy ( $RI > 0.7$ ; explained by compression of the vessels in coarse stroma) (Madjar et al. 1994).

A less frequent but also very useful function of the power Doppler, is its use in combination with “vocal fremitus” (Sohn et al. 1997; Stavros 2004; Kim et al. 2006). In echo-inhomogeneous parenchyma and undefined lesional findings (especially in isodense fatty tissue), the focus can be marked clearly and delineated with a color window placed over the area in question when the patient simultaneously speaks or hums. The vibrations produced in the thorax by the voice cause normal breast tissue to reach a resonance detectable by the CFM earlier than the more solid tissue of the lesion (Fig. 36). However, benign findings cannot be differentiated from malignant finding using this method.

Fig 36: Indistinctly delineated lesion after breast preservation therapy (BPT) (a); confirmation and clear delineation by use of voice fremitus with the power Doppler (b); histology: granulomatous scar tissue

The use of color Doppler for assessing the malignancy of lesional findings can also lead to a higher false-positive rate (lower PPV), and must therefore only be critically evaluated in the context of the B-mode analysis (Schelling et al. 1997). The extent of color signals depends very much on the quality of the equipment used and its adequate adjustment (lowest speed of flow or pulse repetition frequency (PRF)). Sonography is not yet capable of imaging capillary flow without additional use of contrast agents.



A more recent field of use of color Doppler is the monitoring of the reaction of breast tumors during primary (neo-adjuvant) chemotherapy. Reductions in tumor size as well as lowered vascularization, shown sonographically by Doppler, as a sign of a good response to treatment. (Roubidoux et al. 2005; Vallone et al. 2005; Kumar et al. 2007).

Table 5: Indications for use of color Doppler

- Examination of solid lesional findings to determine vascularization and vascularization patterns for further classification of malignancy
- Examination of complex cysts to determine vascularization of echogenic contents of cysts and cyst walls (intracystic papilloma or carcinoma)
- Control of smooth-bordered, hypoechoic homogeneous, in the B-mode non-suspect lesions for lack of vascularization (exclusion of mucinous, medullar carcinoma)
- Examination of echogenic contents of (extended) milk ducts to determine vascularization (papilloma or DCIS)
- Differentiation between necrosis, pus, and tumor proliferation in mastitis
- Monitoring in mastitis (decrease in the intensity of perfusion)
- Examination of scars after BPT to exclude suspected scar recurrence
- Examination of the perfusion pattern of unusual lymph nodes (vessels that do not enter via the hilum are suspect)
- Monitoring of the reaction of a tumor during primary chemotherapy

From the many indications mentioned, one can deduce that CFM is an important addition to, and a fundamental procedure in further sonographic diagnosis in the case of abnormal findings in the breast in the B-mode. The application of the CFM does not represent the final diagnosis, but it is important in making possible indications for further examination with other imaging methods, or for direct clarification by core needle biopsy.

### 3D Sonography

3D sonography enhances the scope of diagnostics by multi-plane additional imaging, especially with the C-plane (the coronal plane) (Rotten et al. 1999; Weismann et al. 2007). With the aid of the C-plane additional and different types of criteria of form can be drawn on, similar to those of mammography. A so-called retraction pattern (star-shaped central structural pattern, which draws towards the lesion, is a sign of invasive growth) points to malignancy; a compression pattern (corresponding with the displacement margin in the A- and B-planes) suggests benignity (Figs. 37, 38).

With new technical equipment lesions can be shown tomographically based on the A, B and C plane (Figs. 39, 40). Plastic images can be shown by surface rendering of the wall structures of cysts, for example, but also of planes freely chosen within a lesion. The response of a carcinoma to primary chemotherapy can be studied by calculation the volume of the malignant lesion (Weismann 2007).

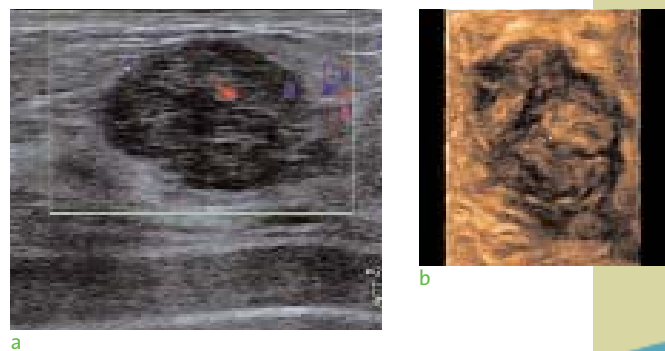


Fig. 37: Predominantly smooth bordered lesion (a); C-plane of a 3D ultrasound (b): Compression pattern: BI-RADS 3; monitoring recommended

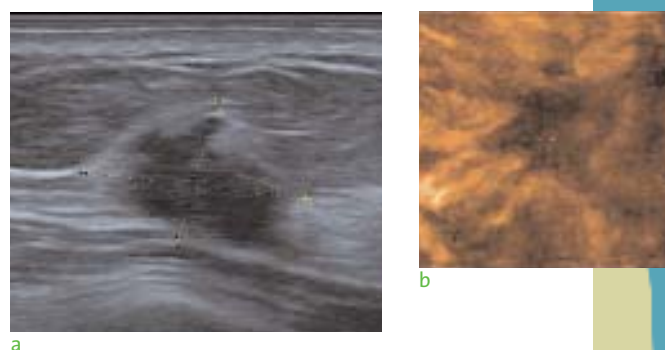


Fig. 38: Irregularly margined, hypoechoic lesion with an echogenic halo (a) BI-RADS 5; confirmation by 3D ultrasound (b): Retraction pattern as a sign of invasive growth; histology: invasive ductal breast carcinoma

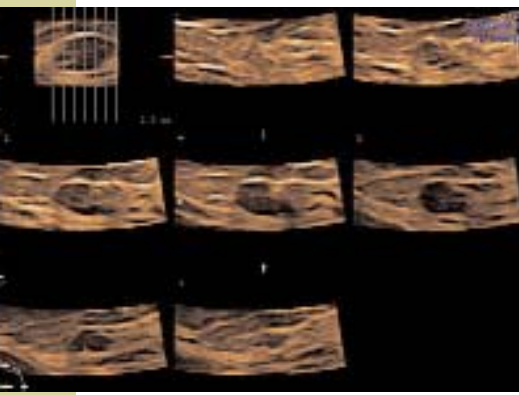

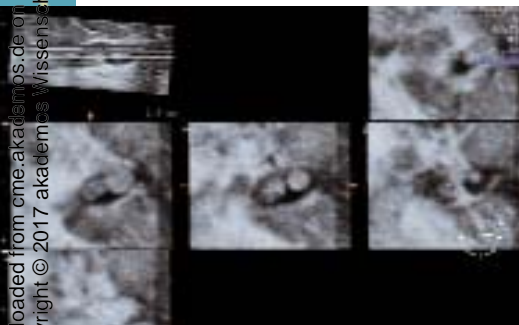


Fig. 39: Tomographic image (TUI) of a fibroadenoma



a



b

Fig. 40: Papilloma of a milk duct (histologically confirmed) in 3D (A-, B-, C-planes and surface rendering) (a); tomographic imaging of the C-plane (undyed) (b)

Experts in 3D ultrasound recommend puncture procedure with dynamic 3D (live 3D or 4D) to determine the exact position of the needle (Weismann et al. 2000, 2007). One must be accustomed to this simultaneous orientation on 3 planes, which has the disadvantage of a reduced frame rate during the procedure. Further assistance is required if one switches from 2D to 3D mode during the procedure.

3D ultrasound can aid further characterization of the lesion and can, in individual cases, (particularly in small early carcinoma with a retraction pattern) possibly give occasion for modification of classification. It must be taken into con-

sideration that not a small number of lesions (benign and malignant) show no distinct pattern in the C-plane (so-called indifferent or indeterminate C-plane) (Figs. 41, 42). The normal B-mode remains the basis for diagnosis, as is the case with the CFM. The 3D module is additionally used for characterization of the lesion when the corresponding equipment is available.

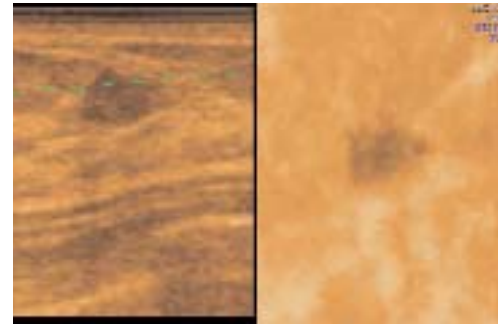


Fig. 41: Lesions without regular margins on all sides, indifferent in the C-plane (VCI mode), histology: fibroadenoma

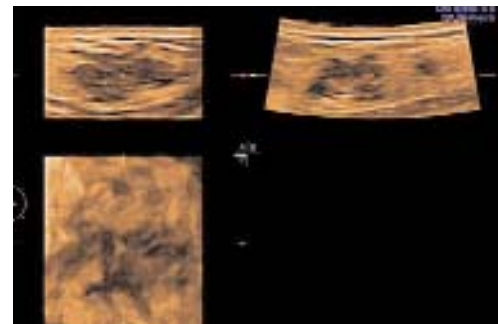


Fig. 42: Lesion with irregular margins (asymptomatic) 3-plane image. The C-plane shows the offshoots in the surrounding tissue, no retraction pattern! Histology: DCIS with microinvasion

### THI (“tissue harmonic imaging”)

In the THI mode, only “harmonious” oscillations, i. e. short waves of the reflected spectrum are filtered to produce the image. This procedure considerably enhances the contrast of the image, albeit with loss of the gray scale value and reduced resolution of the field depth. This method is not suitable as a preset for breast ultrasound (with higher transmitting and receiving frequency in the basic mode). The THI mode can be used in individual cases to identify lesions within fatty tissue more easily (close to the transducer probe), or to enhance their marginal structures in stronger contrast to the surrounding area (Rosen et al. 2001; Mesurolle et al. 2006, 2007) (Fig. 43).

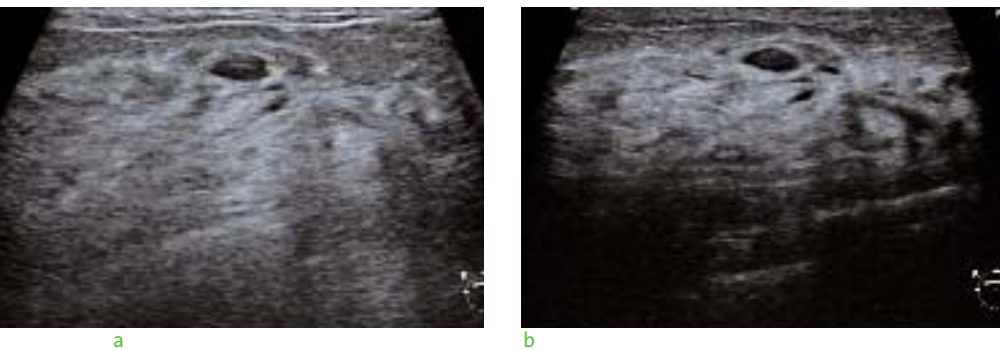


Fig. 43: Fibrocystic mastopathy without THI (a); with THI: sharper contrast with a loss of depth penetration (b)

So-called frequency compound scanning is a modified procedure with less loss of penetration depth. In this method fundamental and harmonic oscillations are used for imaging (Thomas et al. 2007).

#### Compound scanning (SonoCT, CRI, amongst others)

In this technique images from reflectors from different viewing angles are combined to make one image. This module distinguishes the layers more sharply from one another and leads to sharper contours, reduced noise and better contrast (Huber et al. 2002; Kwak et al. 2004). In breast sonography this results in a subjective »clearer« image, which facilitates the detection of structure anomalies and lesional findings (Fig. 44). It should be noted that particular classical characteristics of lesions, such as acoustic shadowing can no longer be assessed, or only to a limited extent (Cha et al. 2005). Furthermore, when using this method, it must be ensured that the image build-up (depending on the manufacturer) is not too slow, so that the image is not unfocussed due to the movement of the probe (blurred).

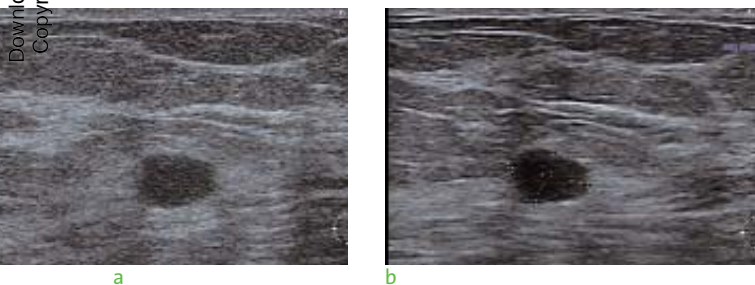


Fig. 44: Parenchyma with cysts, normal B-mode (a); with compound scan and speckle reduction (b)

#### Noise suppression filters (XRes, SRI, amongst others)

The effects of this development are similar to those of compound scanning. Images are clearer due to a more distinct separation of interfaces and enhanced contrast and are therefore easier to „read“. This procedure is also useful in breast ultrasound, which should be used with preset parameters.

#### Panorama image (SieScape, Panorama scan, XTD view, amongst others)

With this technical options provided by some manufacturers, an additional overview image of (only) one scanned plane (!) can be produced by continual progressive guidance of the transducer probe over the whole of the breast (see Fig. 6). This mode shows the type of individual breast well and can be useful for spatial orientation in the case of multifocal carcinomas. This method does not, however, have any primary diagnostic value, but is useful for demonstration and documentation purposes.

#### Elastography

Some manufacturers implement elastography, a procedure by which the elastic characteristics of the scanned tissue are displayed with a color code (Figs. 45-48). It is then possible to differentiate the coarse structure of carcinomas from the more elastic tissue of benign alterations. Here, it also applies that the finding must first be found in the B-mode before it can be subsequently examined by elastography. Additional specificity can be expected with this method. However, as there is overlapping in the elasticity characteristics of benign and malignant tumors, and the results of the method are dependent on the user, there is no final evaluation of the extent to which specificity can be reproducibly increased by elastography (Grunwald et al. 2004; Thomas et al. 2006; Tardivon et al. 2007; Zhi et al. 2007).

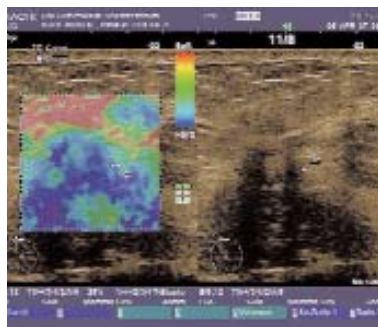
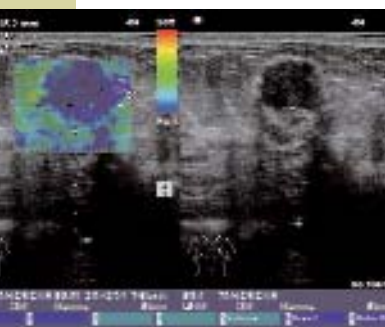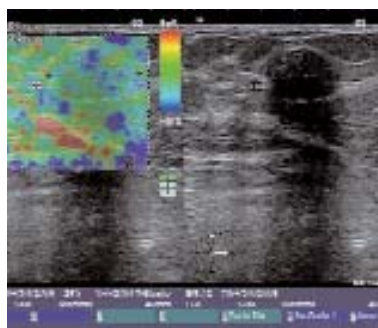
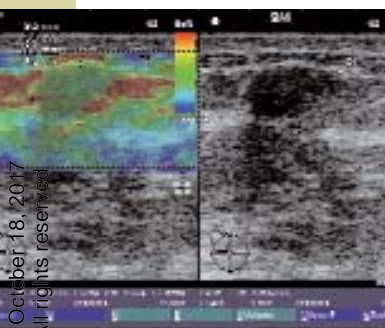


Fig. 45 and 46: Carcinoma image (blue) in elastography



Figs. 47 and 48: Fibroadenoma image (brown-red or green) in elastography

### Breast ultrasound enhanced by contrast media

Some studies have been carried out on the use of contrast media-enhancement to gain evidence of vascularization, using the CFM, in the further analysis of lesions or scar tissue after breast preservation therapy (BPT) (Duda et al. 1993; Bäß et al. 2000; Madjar 2001). After intravenous application of a contrast agent, the lesions were examined by CFM for flooding and washing-out. According to a new study, the precision of classification of lesions using contrast media-enhanced sonography is similar to that of MRI (Ricci et al. 2006).

However, with this procedure (in contrast to MRI), detection of the lesion is necessary in the unenhanced B-mode, and economic aspects, as well as the time needed, must be taken into consideration when using contrast media. It may be questioned whether it would not be more pragmatic to directly use core needle biopsy for final diagnostic classification of unclear lesions.

### Indications for breast ultrasound

Table 6: Clear indications for breast ultrasound

- Diagnostic clarification of the symptomatic breast (palpatory findings, pain)
- Complementary use if mammographical findings are unclear
- Complementary use for X-ray dense breasts
- Complementary use for high-risk patients
- Sonographic localization of lesions detected by MRI
- As an optical guide aid during puncture, core needle or vacuum biopsy
- Post-treatment care
- Monitoring of tumor reactions during primary chemotherapy

Table 7: Plausible, but not evidence-based indications for breast ultrasound

- Extended individual cancer early detection examination, particularly if breasts are too dense or knotty for palpation; for women from about 35-40 years of age
- Breast cancer early detection for women over 50, who do not take part in mammography screening

### Status of sonography in comparison with mammography and MRI in early detection of breast cancer

Sonography is the most important additive method, together with mammography and MRI, when dealing with lesions that can not be finally classified by these methods, or with X-ray dense breasts that are difficult to evaluate.

Reliable, comparative data on sensitivity and specificity of the methods are, in our opinion, not available at present as

1. the methods are still undergoing further technical development,
2. there are no randomized, comparative studies on any of the methods,
3. the collectives examined were not regularly defined regarding breast density, age, or risk status,
4. no uniform criteria were used (methods, interval) for follow-up monitoring to determine parameters.



It has been sufficiently verified that sonography is more sensitive in the examination of invasive carcinoma in X-ray dense breasts than mammography (Kolb et al. 1998; 2000; Leconte et al. 2003; Crystal et al. 2003; Greene et al. 2006). Sonography also exhibits greater diagnostic competence with less frequent carcinoma, such as lobular carcinoma (Berg et al. 2004; Selinko et al. 2004). Sonography ranks behind mammography in the diagnosis of DCIS due to unreliable and less frequent detection of microcalcification. The sonographic sensitivity to asymptomatic DCIS is about 50% (Berg et al. 2004; Boonjunwetwat et al. 2007). Symptomatic DCIS, on the other hand, can be detected better by sonography than by mammography (Chen et al. 2003; Yang et al. 2004).

On the whole, sonography has a diagnostic competence similar to that of mammography in early detection of all carcinoma of the breast (Ohlinger et al. 2003; Berg et al. 2004; Hata et al. 2004; Weining et al. 2005; Grunert et al. 2006; Ohlinger et al. 2006). This justifies its use as a preventative method in a clientele under 50 years of age who do not undergo mammography and a complementary or alternative use in women over 50 with a breast density of ACR 2-4. Such preventative use should, however, only take place under quality assured circumstances (Madjar 2004), as this primary use of sonography is not recommended in the guidelines for early diagnosis of breast cancer (Schulz et al. 2003) and still remains controversial (Cilotti et al. 1997; Kopans 2003; Villeirs 2007).

The good results of sonography in symptomatic findings (including DCIS) and in post-treatment care have been verified and make ultrasound the method of choice for these indications. At present, the complementary use of mammography and sonography offers the greatest security in asymptomatic patients.

According to the latest studies, the sensitivity of MRI appears to be clearly superior to that of the other methods (Schouten van der Velden et al. 2006; Lehmann 2006; Kuhl 2007a, b) and could lead to a long-term paradigm shift in the early diagnosis of breast cancer. The methodical performance of MRI, however, remains to be standardized. A combination of ultrasound and MRI could be promising and if studied, would offer a good opportunity of evaluating the capacities of sonography.

CME Prakt Fortbild Gynakol Geburtsmed Gynakol Endokrinol 2008; 4(1): 50–72

### Keywords

Breast ultrasound, sonography of the breast, breast cancer, DCIS

### References

- AMERICAN COLLEGE OF RADIOLOGY (ACR).** Breast Imaging Reporting and Data System Atlas (BI-RADS® Atlas). Reston, Va: ©American College of Radiology 2003.
- BÄZ E, MADJAR H, REUSS C, VETTER M, HACKELÖER B, HOLZ K.** The role of enhanced Doppler ultrasound in differentiation of benign vs. malignant scar lesions after breast surgery for malignancy. *Ultrasound Obstet Gynecol* 2000; 15: 377–382.
- BARTH V.** Mammadiagnostik. Stuttgart: Thieme 2005.
- BERG WA, GUTIERREZ L, NESSAIVER MS, CARTER WB, BHARGAVAN M, LEWIS RS, IOFFE OB.** Diagnostic accuracy of mammography, clinical examination, US, and MR imaging in preoperative assessment of breast cancer. *Radiology* 2004; 233: 830–849.
- BLOHMER JU, OELLINGER H, SCHMIDT C, HUFNAGL P, FELIX R, LICHTENEGGER W.** Comparison of various imaging methods with particular evaluation of color Doppler sonography for planning surgery for breast tumors. *Arch Gynecol Obstet* 1999; 262: 159–171.
- BOONJUNWETWAT D, CHYUTIPRAIWAN U, SAMPATANUKUL P, CHATAMRA K.** Sensitivity of mammography and ultrasonography on detecting abnormal findings of ductal carcinoma in situ. *J Med Assoc Thai* 2007; 90: 539–545.
- BUCHBERGER W, NIEHOFF A, OBRIST P, DEKOEKOEK-DOLL P, DUNSER M.** Clinically and mammographically occult breast lesions: detection and classification with high resolution sonography. *Semin Ultrasound CT MR* 2000; 21: 325–336.
- CHA JH, MOON WK, CHO N, CHUNG SY, PARK SH, PARK JM, HAN BK, CHOE YH, CHO G, IM J-G.** Differentiation of benign from malignant solid breast masses: conventional versus spatial compound imaging. *Radiology* 2005; 237: 841–846.
- CHAN SW, CHEUNG PS, CHAN S, LAU SS, WONG TT, MA M, WONG A, LAW YC.** Benefit of Ultrasonography in the Detection of Clinically and Mammographically Occult Breast Cancer. *World J Surg* 2007; Epub ahead of print.
- CHEN SC, CHEUNG YC, LO YF, CHEN MF, HWANG TL, SU CH, HSUEH S.** Sonographic differentiation of invasive and intraductal carcinomas of the breast. *BJR* 2003; 76: 600–604.
- CHEN SC, CHEUNG YC, SU CH ET AL.** Analysis of sonographic features for the differentiation of benign and malignant breast tumors of different sizes. *Ultrasound Obstet Gynecol* 2004; 23: 199–193.
- CHRISTENSEN AF, ALO-SULIMAN N, NIELSEN KR ET AL.** Ultrasound guided drainage of breast abscesses: results in 151 patients. *BJR* 2005; 78: 186–188.
- CILOTTI A, BAGNOLESI P, MORETTI M ET AL.** Comparison of the diagnostic performance of high-frequency ultrasound as a first- or second-line diagnostic tool in non-palpable lesions of the breast. *Eur Radiol* 1997; 7: 1240–1244.



- CRYSTAL P, STRANO SD, SHCHARANSKI S, KORETZ MJ.** Using sonography to screen women with mammographically dense breasts. *AJR* 2003; 181:177–182.
- DEL CURA JL, ELIZAGARAY E, ZABALA R, LEGÓRBURU A, GRANDE D.** The use of unenhanced Doppler sonography in the evaluation of solid breast lesions. *AJR* 2005; 184: 1788–1794.
- DEGENHARDT F, FRENZ JP, HARMS A.** Manual Mammasonographie. Stuttgart: Thieme 2000.
- DEUTSCHE KREBSGESELLSCHAFT E.V.** Diagnostik, Therapie und Nachsorge des Mammakarzinoms der Frau. Eine nationale S3-Leitlinie. 2004. [www.dggg.de](http://www.dggg.de). Link: Leitlinien. Zugriff am 31.10.2007.
- DILLON MF, HILL AD, QUINN CM, O'DOHERTY A, McDERMOTT EW, O'HIGGINS N.** The accuracy of ultrasound, stereotactic, and clinical core biopsy in the diagnosis of breast cancer, with an analysis of false-negative cases. *Ann Surg* 2005; 242:701–707.
- DI NUBILA B, CASSANO E, URBAN LA, FEDELE P, ABBATE F, MAISONNEUVE P, VERONESI P, RENNE G, BELLOMI M.** Radiological features and pathological-biological correlations in 348 women with breast cancer under 35 years. *Breast* 2006; 15: 744–753.
- DUDA VF, RODE G, SCHLIEF R.** Echocontrast agent enhanced color flow imaging of the breast. *Ultrasound Obstet Gynecol* 1993; 3: 191–194.
- DUDA VF, SCHULZ-WENDTLAND R (Eds).** Mammadiagnostik. Berlin: Springer 2004.
- FISCHER D, STÖCKELHUBER B, DIESING D, CORDES T, FRIEDRICH M.** Sonographie benigner und maligner Mammatumoren. *Der Gynäkologe* 2006; 39: 509–515.
- FISCHER U, BAUM F (Eds).** Trainer Mammadiagnostik. Stuttgart: Thieme 2005.
- FISCHER U, HELBICH T (Eds).** ACR BI-RADS. Stuttgart: Thieme 2006.
- GEORGIAN-SMITH D, TAYLOR KJ, MADJAR H, GOLDBERG B, MERRITT CR, BOKOBSA J, RUBIN E, MENDELSON EB, FORNAGE BD, ROUSE G, WADDEN NA, DEWBURY KC, COSGROVE DO, SCHMIDT R.** Sonography of palpable breast cancer. *J Clin Ultrasound* 2000; 28(5): 211–6.
- GRAF O, HELBICH TH, HOPF G, GRAF C, SICKLES EA.** Probably benign breast masses at US: is follow-up an acceptable alternative to biopsy? *Radiology* 2007; 244: 87–93.
- GREENE T, COCILOVO C, ESTABROOK A, CHINITZ L, GIULIANO C, ROSENBAUM S, SMITH S, TARTTER P.** A single institution review of new breast malignancies identified solely by sonography. *J Am Coll Surg* 2006; 203: 894–898.
- GRUNERT JH, HILLE H.** Mammasonographie und Mammographie in der dezentralen Brustkrebsdiagnostik. *GebFra* 2006, 66: 1–5.
- GRUNWALD S, OHLINGER R, SCHULZ K, KÖHLER G.** Mammatumoren – Erste Ergebnisse mit der SonoElastographie. *Ultraschall Med* 2004; 25(Suppl 1): DOI: 10.1055/s-2004-834061.
- HATA T, TAKAHASHI H, WATANABE K, TAKAHASHI M, TAGUCHI K, ITOH T, TODO S.** Magnetic resonance imaging for preoperative evaluation of breast cancer: a comparative study with mammography and ultrasonography. *J Am Coll Surg* 2004; 198: 190–197.
- HILLE H, VETTER M, HACKELÖER BJ.** Neubewertung der Mammasonographie in der gegenwärtigen Mammadiagnostik. *Ultraschall in Med* 2004; 25: 411–417.
- HILLE H, VETTER M, HACKELÖER BJ.** Die Eignung der hochfrequenten Sonographie zur Diagnostik des DCIS. *Ultraschall Med* 2007; 28: 307–312.
- HOLTFRETER A, KÖHLER G, KOLYSCHKOW GRUNWALD S, FRESE H, OHLINGER R.** Sonographie-BI-Rads-Kategorie-3-Kontrolle versus Stanzbiopsie. *Senologie* 2006; 3, DOI: 10.1055/s-2006-953689.
- HOUSSAMI N, IRWIG L, SIMPSON JM, MCKESSAR M, BLOME S, NOAKES J.** Sydney breast imaging accuracy study: comparative sensitivity and specificity of mammography and sonography in young women with symptoms. *AJR* 2003; 180: 935–940.
- HUBER S, WAGNER M, MEDL M, CZEMBIREK H.** Real-time spatial compound imaging in breast ultrasound. *Ultrasound Med Biol* 2002; 28: 155–163.
- KIM MJ, KIM EU, YOON JH, LEE JY, YOUNG J, KIM BM, OH KK.** Application of power Doppler vocal fremitus sonography in breast lesions. *J Ultrasound Med* 2006; 2: 897–906.
- KLUG U, OHLINGER R, SCHIMMING A, KÖHLER G.** Mammasonographie als Erstuntersuchung im Vergleich zur Mammographie bei asymptomatischen Frauen der Altersgruppe 40–49 Jahre. *Ultraschall in Med* 2004; 25: DOI: 10.1055/s-2004-834009.
- KOLB TM, LICHY J, NEWHOUSE JH.** Occult cancer in women with dense breasts: detection with screening US – diagnostic yield and tumor characteristics. *Radiology* 1998; 207: 191–199.
- KOLB TM, LICHY J, NEWHOUSE JH.** Comparison of the performance of screening mammography, physical examination, and breast US and evaluation of factors that influence them: An analysis of 27,825 patient evaluations. *Radiology* 2002; 225: 165–175.
- KONSENSUSPAPIER: EMPFEHLUNGEN ZUR NACHSORGE NACH MAMMAKARZINOM.** Österreichische Gesellschaft für Senologie (ÖGS), Arbeitsgemeinschaft für Gynäkologische Onkologie (AGO), Österreichische Gesellschaft für Gynäkologie und Geburtshilfe (ÖGGG). *Senologie* 2007; 3: 158–160.
- KOPANS DB.** Effectiveness of US breast cancer screening remains to be demonstrated (letter). *Radiology* 2003; 227: 606.
- KRAINICK-STROBEL U, HAHN M, DUDA VF, PAEPKE U, PETRICH S, SCHELER P, SCHWARZ-BÖCKER U, SINN HP, HEYWANG-KÖBRUNNER S, SCHREER I, AG MIMI DER DGS.** Konsensempfehlung zu Anwendung und Indikationen der Vakuumbiopsie der Brust unter Ultraschallsicht. Arbeitsgruppe Minimalinvasive Mammainterventionen. *GebFra* 2005; 65: 526–529.
- KUHL CK, SCHRADING S, BIELING HB, WARDELMANN E, LEUTNER CC, KOENIG R, KUHN W, SCHILD HH.** MRI for diagnosis of pure ductal carcinoma in situ: a prospective observational study. *Lancet* 2007; 370: 485–492.

- KUHL CK.** The current status of breast MR Imaging. Part 1. Choice of technique, image interpretation, diagnostic accuracy, and transfer to clinical practice. *Radiology* 2007a; 244: 356–378.
- KUHL CK.** The current status of breast MR Imaging. Part 2. Clinical applications. *Radiology* 2007b; 244: 672–691.
- KUMAR A, SINGH S, PRADHAN S, SHUKLA RC, ANSARI MA, SINGH TB, SHYAM R, GUPTA S.** Doppler ultrasound scoring to predict chemotherapeutic response in advanced breast cancer. *WJSO* 2007; 5:99. DOI: 10.1186/1477-7819-5-99.
- KWAK JY, KIM EK, YOU JK, OH KK.** Variable breast conditions. Comparison of conventional and real-time compound ultrasonography. *J Ultrasound Med* 2004; 23:85–96.
- LAQALLA R, MIDRI M.** Image quality control in breast ultrasound. *Eur J Radiol* 1998; 27(Suppl 2): 229–233.
- LECONTE I, FEGER C, GALANT C, BERLIÈRE M, BERG BV, D'HOORE W, MALDAGUE B.** Mammography and subsequent whole-breast sonography of nonpalpable breast cancers: the importance of radiologic breast density. *AJR* 2003; 167:1675–1679.
- LEE SW, CHOI HY, BAEK SY.** Role of color and power Doppler imaging in differentiating between malignant and benign solid breast masses. *J Clin Ultrasound* 2002; 30: 459–464.
- LEE WJ, CHU JS, HUANG CS, CHANG MF, CHANG KJ, CHEN KM.** Breast cancer vascularity: color Doppler sonography and histopathology study. *Breast Cancer Res Treat* 1996; 37: 291–298.
- LEHMANN CD.** Role of MRI in screening women at high risk for breast cancer. *J Magn Reson Imaging* 2006; 24: 964–970.
- MADJAR H.** *Kursbuch Mammasonographie.* Stuttgart: Thieme 2005.
- MADJAR H.** Vorteile und Grenzen der Brust-Ultraschall-diagnostik. *Gynäkol Geburtshilfliche Rundsch* 2002; 42(4): 185–90.
- MADJAR H.** Contrast ultrasound in breast tumor characterization: present situation and future tracks. *Eur Radiol* 2001; 11(Suppl 3): E41–6. No abstract available.
- MADJAR H, MENDELSON EB, JELLINS J.** *The Practice of Breast Ultrasound.* Stuttgart: Thieme 2008.
- MADJAR H, SAUERBREI W, PROMPELER HJ, WOLFARTH R, GUFLER H.** Color Doppler and duplex flow analysis for classification of breast lesions. *Gynecol Oncol* 1997; 64: 392–403.
- MADJAR H, OHLINGER R, MUNDINGER A, WATERMANN D, FRENZ JP, BADER W, SCHULZ-WENDTLAND R, DEGENHARDT F.** BI-RADS analoge DEGUM Kriterien von Ultraschallbefunden der Brust – Konsens des Arbeitskreises Mammasonographie der DEGUM. *Ultraschall in Med* 2006; 27(4): 374–9.
- MARQUET KL, WOLTER M, HANDT S, RATH W, STRESSIG R, KOZLOWSKI P, FUNK A.** Mammasonographische Dignitätskriterien unter besonderer Berücksichtigung der Tumorgroße. *Ultraschall Med* 2002; 23: 383–387.
- MESUROLLE B, BINING HJS, KHOURY ME, BARHDADI A, KAO E.** Contribution of tissue harmonic imaging and frequency compounding imaging in interventional breast sonography. *J Ultrasound Med* 2006; 25: 845–855.
- MESUROLLE B, HELOU T, EL-KHOURY M, EDWARDES M, SUTTON EJ, KAO E.** Tissue harmonic imaging, frequency compound imaging, and conventional imaging. Use and benefit in breast sonography. *J Ultrasound Med* 2007; 26: 1041–1051.
- OHLINGER R, LORENZ G, SCHWESINGER G, WARM M.** *Mammasonographie.* Berlin: de Gruyter 2002.
- OHLINGER R, KRAUS RG, OELLIG F, SCHWESINGER G, KÖHLER G.** Diagnostische Wertigkeit von Palpation, Mammographie und Mammasonographie in der präoperativen Diagnostik des Mammakarzinoms. *GebFra* 2003; 63: 1246–1255.
- OHLINGER R, KLEIN GM, KÖHLER G.** Ultrasound of the breast – value of sonographic criteria for the differential diagnosis of solid lesions. *Ultraschall Med* 2004; 25: 48–53.
- OHLINGER R, HEYER H, THOMAS A, PAEPKE S, WARM H, KLUG U, FRESE H, SCHULZ K, SCHIMMING A, SCHWESINGER G, KÖHLER G, WODNY M, KOHLMANN T, GRUNWALD S.** Non-palpable breast lesions in asymptomatic women: diagnostic value of initial ultrasonography and comparison with mammography. *Anticancer Res* 2006; 26: 3943–3955.
- OHTA T, OKAMOTO K, KANEMAKI Y, TSUJIMOTO F, NAKAJIMA Y, FUKUDA M, SUKA M.** Use of ultrasonography as an alternative modality for first-line examination in detecting breast cancer in selected patients. *Clin Breast Cancer* 2007; 7: 624–626.
- OSAKO T, TAKAHASHI K, IWASE T, IJIMA K, MIYAGI Y, NISHIMURA S, TADA K, MAKITA M, AKIYAMA F, SAKAMOTO G, KASUMI F.** Diagnostic ultrasonography and mammography for invasive and noninvasive breast cancer in women aged 30 to 39 years. *Breast Cancer* 2007; 14(2): 229–233.
- PETERS-ENGL C, FRANK W, LEODOLTER S, MEDL M.** Tumor flow in malignant breast tumors measured by Doppler ultrasound: an independent predictor of survival. *Breast Cancer Res Treat* 1999; 54: 65–71.
- RAGETH CJ, RICKLIN ES, SCHOLL B, SAURENMANN E.** Behandlung puerperaler Mammaabszesse durch wiederholte Punktionen und perorale Antibiotikagabe. *Z Geburtshilfe Neonatol* 2004; 208: 170–173.
- RICCI P, CANTISANI V, BALLESEO L, PAGLIARA E, SALLUSTI E, DRUDI M, TRIPPA F, CALASCIBETTA F, ERTURK MS, MODESTI M, PASSARIELLO R.** Benign and malignant breast lesions: efficacy of real time contrast-enhanced ultrasound vs. magnetic resonance imaging. *Ultraschall Med* 2006; 27: 57–62.
- RIEBE E, GÜNTHER K, SCHULZ K, KÖHLER G, SCHIMMING A, SCHWESINGER G, OHLINGER R.** Recurrent disease after breast preserving therapy (BPT) and radiation therapy for breast cancer – diagnostic yield of palpation, mammography and ultrasonography. *Ultraschall Med* 2007; 28: 394–400.
- ROSEN EL, SOO MS.** Tissue harmonic imaging sonography of breast lesions: improved margin analysis, conspicuity, and image quality compared to conventional ultrasound. *Clin Imaging* 2001; 25: 379–384.
- ROTTEN D, LEVAILLANT JM, ZERAT L.** Analysis of normal breast tissue and of solid breast masses using three-dimensional ultrasound mammography. *Ultrasound Obstet Gynecol* 1999; 14(2): 114–24.
- ROUBIDOUX MA, LeCARPENTIER GL, FOWLKES JB, BARTZ B, PAI D, GORDON SP, SCHOTT AF, JOHNSON TD, CARSON PL.**

- Sonographic evaluation of early-stage breast cancers that undergo neoadjuvant chemotherapy. *J Ultrasound Med* 2005; 24: 885–895.
- SCHELLING M, GNIRS J, BRAUN M.** Optimized differential diagnosis of breast lesions by combined B-mode and color Doppler sonography. *Ultrasound Obstet Gynecol* 1997; 10: 48–53.
- SCHOUTEN VAN DER VELDEN AP, BOETES C, BULT P, WOBBS T.** The value of magnetic resonance imaging in diagnosis and size assessment of in situ and small invasive breast carcinoma. *Am J Surg* 2006; 192:172–178.
- SCHULZ KD, ALBERT US (Eds).** Sufe-3-Leitlinie, Brustkrebs-früherkennung. München: Zuckschwert 2003.
- SCHULZ-WENDTLAND R, BOCK K, AICHINGER U, DE WAAL J, BADER W, ALBERT US, DUDA F.** Mamma-Sonographie mit 7,5 MHz versus 13 MHz: Ist eine Verbesserung der diagnostischen Sicherheit im Rahmen der komplementären Mammadiagnostik möglich? *Ultraschall Med* 2005; 26: 209–215.
- SEHGAL CM, WEINSTEIN SP, ARGER PH, CONAN EF.** A review of breast ultrasound. *J Mammary Gland Biol Neoplasia* 2006; 11:113–123.
- SELINKO VL, MIDDLETON LP, DEMPSEY PJ.** Role of sonography in diagnosing and staging invasive lobular carcinoma. *J Clin Ultrasound* 2004; 32: 323–332.
- SMITH RA.** The evolving role of MRI in the detection and evaluation of breast cancer. *NEJM* 2007; 356:1362–1364.
- SOHN C, BAUDENSTIEL A.** Differential diagnosis of mammary tumors with vocal fremitus in sonography: preliminary report. *Ultrasound Obstet Gynecol* 1995; 6:205–207.
- SOHN C, BLOHMER JU.** Mammasonographie. Stuttgart: Thieme 2006.
- SOHN C, BLOHMER J-U, HAMPER UM.** Breast Ultra-sound. Stuttgart: Thieme 1999.
- STAVROS AT, THICKMAN D, RAPP CL, DENNIS MA, PARKER SH, SISNEY GA.** Solid breast nodules: use of sonography to distinguish between benign and malignant lesions. *Radiology* 1995; 196: 123–134.
- STAVROS AT.** Breast Ultrasound. Philadelphia: Lippincott Williams & Wilkins 2004.
- STRANO S, GOMBOS EC, FRIEDLAND O, MOZES M.** Color Doppler imaging of fibroadenomas of the breast with histopathologic correlation. *J Clin Ultrasound* 2004; 32:317–322.
- TARDIVON A, EL KHOURY C, THIBAUT F, WYLER A, BARREAU B, NEUENSCHWANDER S.** Elastosonography of the breast: prospective study of 122 lesions. *Journal de Radiologie* 2007; 88: 657–662.
- THOMAS A, FISCHER T, FREY H, OHLINGER R, GRUNWALD S, BLOHMER J-U, WINZER K-J, WEBER S, KRISTIANSEN G, EBERT B, KÜMMEL S.** Real-time elastography – an advanced method of ultrasound: first results in 108 patients with breast lesions. *Ultrasound Obstet Gynecol* 2007; 28: 335–340.
- THOMAS A, FILIMONOW S, SLOWINSKI T, FISCHER T.** Steigerung der Bildqualität bei der Dignitätsbeurteilung mammasonografischer Herde mittels Frequenz-Compounding. *Ultraschall in Med* 2007; 28:387–393.
- VALLONE P, D'ANGELO R, FILICE S, PETROSINO T, RINALDO M, DE CHIARA A, GALLIPOLI A.** Color-doppler using contrast medium in evaluating the response to neoadjuvant treatment in patients with locally advanced breast carcinoma. *Anticancer Res* 2005; 25: 595–599.
- YANG WT, TSE GMK.** Sonographic, mammographic, and histopathologic correlation of symptomatic ductal carcinoma in situ. *AJR* 2004; 182:101–110.
- VILLEIRS GM.** Is there a role for sonography in breast cancer screening? *JBR-BTR* 2007; 90: 155–158.
- WATERMANN D, MADJAR H, SAUERBREI W, HIRT V, PROMPELER H, STICKELER E.** Assessment of breast cancer vascularisation by Doppler ultrasound as a prognostic factor of survival. *Oncol Rep* 2004;11(4): 905–10.
- WEINING C, WEINING-KLEMM O, BARTH V.** Die Ein-Ebenen-Mammographie in Kombination mit der Mammasonographie versus Zwei-Ebenen-Mammographie zur Untersuchung der weiblichen Brust. *Neues Konzept für die Früherkennung von Brustkrebs. GebFra* 2005; 65: 289–296.
- WEISMANN CF, FORSTNER R, PROKOP E, RETTENBACHER T.** Three dimensional targeting: a new three-dimensional ultrasound technique to evaluate needle position during breast biopsy. *Ultrasound Obstet Gynecol* 2000; 14: 383–393.
- WEISMANN CF.** Role of colour Doppler ultrasound in breast imaging. *EJC Supplements* 2006; 4: 41–42.
- WEISMANN C, HERGAN K.** Aktueller Stand der 3D-/4D-Volumensonografie. *Ultraschall Med* 2007; 28: 273–282.
- WU YC, CHEN DR, KUO SJ.** Personal experience of ultrasound-guided 14-gauge core biopsy of breast tumor. *Eur J Surg Oncol* 2006; 32: 715–718.
- WWW.DEGUM.DE.**
- WWW.SENOLOGIE.ORG.**
- ZHI H, OU B, LUO BM, FENG X, WEN Y-L, YANG H-Y.** Comparison of ultrasound elastography, mammography, and sonography in the diagnosis of solid lesions. *J Ultrasound Med* 2007; 26: 807–815.



Dr. med. Heino Hille

Lappenbergsallee 50  
20257 Hamburg

Dr. Hille completed his training as a specialist for gynecology and obstetrics in the Hamburg Clinics and started to practice in Hamburg in 1981. He has completed training in gynecological and prenatal ultrasound diagnostics and has the DEGUM II qualification in prenatal diagnosis and breast sonography. The subject of his doctoral thesis was Doppler sonography of the uterine artery. The main focus of his practice is gynecological prenatal sonography and breast sonography. He has published works on diagnostics of the breast and prenatal medicine.

#### Conflict of interest

The authors declare that there is no conflict of interest as defined by the guidelines of the International Committee of Medical Journal Editors (ICMJE; [www.icmje.org](http://www.icmje.org)).

#### Manuscript information

Submitted on: 01.10.2007

Accepted on: 27.10.07

# CME-Continuing Medical Education

## Breast ultrasound

### Question 1

Breast sonography is an imaging method used for the diagnosis of

- a. only of benign alterations of the breast,
- b. only of cysts,
- c. mainly carcinomas of the breast,
- d. inflammation of the breast,
- e. all the previously named alterations and conditions.

### Question 2

Sonographic documentation should include the following information:

- a. the identification of the patient,
- b. the age of the patient,
- c. the time of the examination,
- d. the type of ultrasound equipment used,
- e. the position of the patient's body.

### Question 3

Sonographic readings of a lesion include

- a. a description of the thickness of the skin,
- b. a description of the marginal structure of the lesion,
- c. a description of breast density,
- d. a description of the size of the breast,
- e. the distance from the pectoral muscle.

### Question 4

The term BI-RADS defines

- a. the density of the breast,
- b. the classification of the ultrasound equipment,
- c. the echogenicity of the glandular tissue,
- d. classification according to benignity and malignancy criteria,
- e. the risk status of the patient.

### Question 5

The sonographic characteristics of a malignant lesion are

- a. a bilateral shadow on the margins of the lesion,
- b. a retrotumoral increase in sound amplification,
- c. capsule formation,
- d. an echo-rich margin,
- e. a compression pattern on the C-plane of 3D ultrasound.

### Question 6

Which of the following are sonographic characteristics of benign lesions?

- a. Microlobulation.
- b. Echo-inhomogeneousness.
- c. Increased vascularization.
- d. Spiculation.
- e. Smooth margins.

### Question 7

Breast sonography may be performed as evidenced based:

- a. as general screening for breast cancer,
- b. as a substitute for mammography,
- c. as an examination preceding mammography,
- d. in post-treatment care,
- e. in women over 50 years of age.

### Question 8

The use of color Doppler in breast ultrasound is

- a. unimportant,
- b. only meaningful if used by experts,
- c. harmful,
- d. more important than the B-mode,
- e. important for differentiating lesions of the breast.

### Question 9

3D ultrasound in breast sonography

- a. makes the classification of lesional findings more difficult,
- b. is time-wasting,
- c. offers additional criteria for the classification of lesions,
- d. represents the total volume of the breast,
- e. helps to detect lesions.

### Question 10

Breast sonography is

- a. not a method for early detection of breast cancer,
- b. unsuitable for young women,
- c. unsuitable for older women,
- d. contraindicated in high-risk patients,
- e. is useful in the examination of X-ray dense breasts.