

# Surgical treatment of breast cancer

Fakher Ismaeél

Klinik für Frauenheilkunde und Geburtshilfe,  
Charité – Universitätsmedizin, Berlin  
Germany

Reviewers: Gert Räber, Berlin  
and Andree Faridi, Hamburg

## Summary

As is true for all surgical techniques in breast cancer, the aim of breast conserving therapy is the removal of the tumor with clear surgical margins. In connection with radiation therapy, breast conserving therapy is an effective procedure. Tylectomy/lumpectomy and partial mastectomy with breast reconstruction using myocutaneous flaps are standardized procedures. In case of a mastectomy, reconstruction can be performed with alloplastic material (expander, prosthesis) as well as autogenous tissue (latissimus dorsi flap, pedicle/free transverse rectus abdominis myocutaneous flap [TRAM]). Nipple reconstruction is mainly performed using local flaps and tattoos. According to recent findings, a sentinel lymph node biopsy instead of axillary lymph node dissection is also sufficient in advanced stages of breast cancer and has the advantage of reducing the morbidity in the shoulder-arm area.

## Introduction

In Germany, an average of 5500 women per year are diagnosed with breast cancer. Thus, every 9<sup>th</sup> to 10<sup>th</sup> woman will suffer from breast cancer throughout her life. This makes breast cancer the most frequent malignant tumor in women.

Surgical management of breast cancer has changed fundamentally within the last three decades. Up until the 1980's, Halsted total mastectomy was the first-line therapy for breast cancer. It includes the complete resection of the mammary gland, the pectoralis major muscle, the pectoralis minor muscle and a level 3 lymph node dissection. It was thought that a radical operation would guarantee the best cure rate. In the 1960's, B. Fisher and U. Veronesi developed the thesis that breast cancer represents a systemic disease, also in the primary stages and thus concluded that radical surgical management does not greatly affect the survival rate. On the basis of this novel approach to surgery combined with postoperative breast irradiation, they then developed the concept of breast-conserving therapy. In 1969, Veronesi applied for the first randomized study at the WHO, which compared quadrantectomy, an extensive resection of the tumor with a 2 cm to 3 cm safety margin including a skin peddle, combined with postoperative radiation with the conventional Halsted total mastectomy. Due to the unconventional concept, it took until 1973 for the first patient to be admitted to the study. In the first

results, both groups had a similar survival rate. The main criticism, however, concerned the short postoperative observation period. However, within the last years these results have been confirmed in three extensive studies (van Dongen et al. 2000; Fisher et al. 2002; Veronesi et al. 2002) after a follow-up of up to 29 years. These results now are the scientific basis for breast conserving treatment of breast cancer (level of evidence 1a).

In all studies, an increased local recurrence rate was found in those patients treated with breast conserving therapy. The significance of this outcome was discussed for a long time. However, recent studies have proven that the local recurrence of breast cancer can be the origin of distal metastases (Hellmann 1997; Hölzel et al. 2001; Koscielny et al. 1999). A complete in sano resection of the invasive and non-invasive tumor in combination with irradiation is thus an indispensable prerequisite for breast conserving treatment.

So far, there is no definite data on the size of the safety margin that allows for a complete resection of the tumor. The S3 guidelines from the German Cancer society (Deutsche Krebsgesellschaft) and the German society for Gynecology and Obstetrics (Deutsche Gesellschaft für Gynäkologie und Geburtshilfe, DGGG) on the diagnosis and therapy of breast cancer recommend a safety margin of 1 mm in invasive carcinomas and a safety margin of 5 mm in ductal carcinoma in situ. Also in the presence of an extensive intraductal component in invasive cancer, a safety margin of at least 5 mm in the healthy tissue should be adhered to.

If the lesion is not palpable, its location has to be marked by inserting a wire into the lesion prior to surgery. The surgical specimen is scanned by either sonography or radiography, depending on which technique was used when placing the wire. This control is a proof that the suspected tissue was excised with negative margins.

Indications for breast-conserving therapy are:

- invasive breast cancer with a favorable tumor breast ratio
- invasive breast cancer with intraductal components, provided that complete excision with negative margins is feasible
- locally confined ductal carcinoma in situ

### Surgical techniques in breast-conserving procedures tylectomy/lumpectomy

The incision for tumor resection (Fig. 1) should follow the Langer's lines. It is usually an elliptical incision and should be made directly over the tumor. A radial incision can be appropriate in individual cases, for example if the tumor is located in the axillary extension, which would allow the sentinel lymph node biopsy to be performed simultaneously. If the tumor is superficial, the overlying skin is resected together with the specimen. "Tunneling" or the enforcement of a periareolar cut to resect the tumor are not recommended. The excision of the core biopsy duct is also no longer recommended.

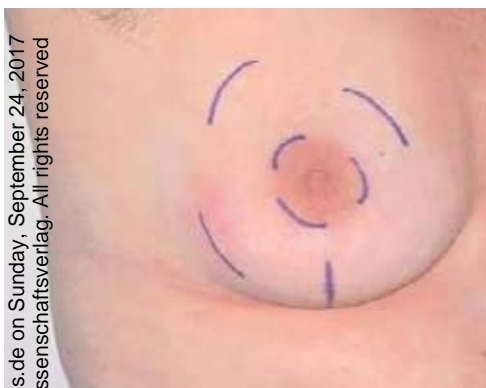

Figure 1: elliptical/radial incision in breast-conserving therapy

In the course of the tumor excision, also in an elliptical incision of the skin, the radial arrangement of the lactic ducts has got to be considered. Thus, a segmental resection should be planned.

Directly before the extirpation of the tumor, it should be unmistakably marked so that the pathologist can precisely examine the excision margins. Despite the small safety margin, the wound cavity can turn out relatively large, which has got to be filled with an intramammary flap (Fig. 2), as otherwise seromas with excessive scar tissue could have influence on the postoperative radiation and the subsequent imaging diagnostics. The tumor bed can be marked with a titanium clip, in order to precisely place the boost during radiation, which is today a considerable dose.

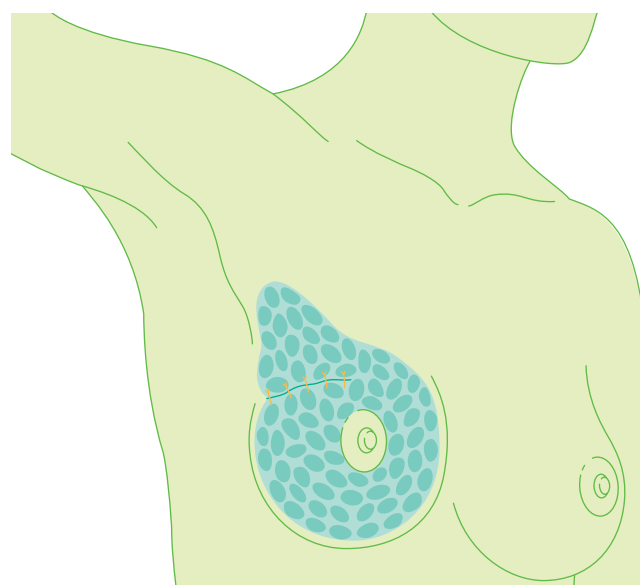
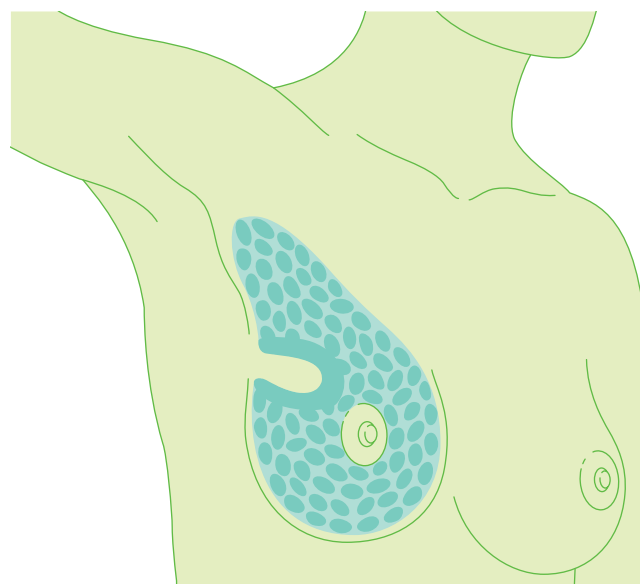


Figure 2: Graphic representation of a lumpectomy with an intramammary flap

### Partial mastectomy with autogenous tissue transplantation

In some cases, a substantial part of the breast has to be excised, for example in a large tumor-breast ratio, in order to achieve an acceptable cosmetic result after tylectomy, if there is a great area with suspicious microcalcifications or an extensive DCIS.

In order to preserve a smaller or normally sized breast, the defects should be compensated with a myocutaneous tissue flap. This procedure allows wide negative safety margins. In most cases, the latissimus-dorsi muscle is used (Fig. 3). It is a sustainable flap that can undergo postoperative irradiation as it is supplied by the thoracodorsal vessels.

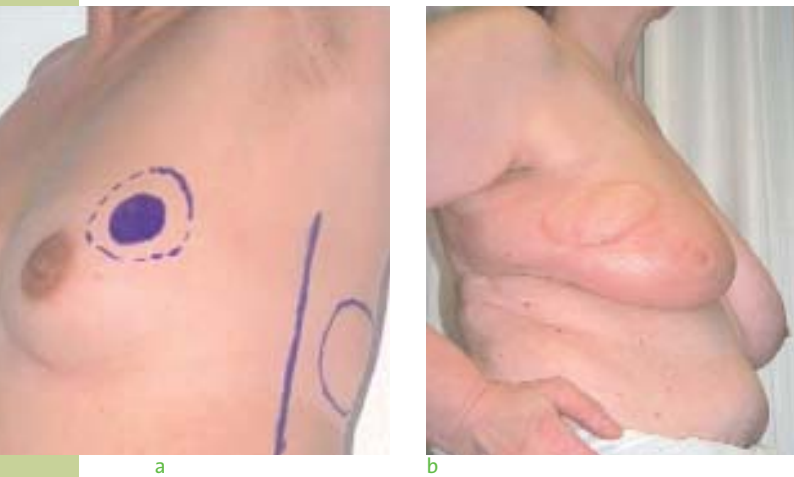

Figure 3: Partial mastectomy: preoperative drawing (a) and postoperative result (b)

### Oncoplastic surgery

Oncoplastic surgery is another form of breast conserving therapy (Fig. 4). In cases of macromastia, reduction mammoplasty can be performed in order to reconstruct the breast in healthy tissue after resection of the tumor. The position of the nipple has to be taken into account depending on the position of the tumor. The free transplantation of the nipple with surgical pathology of the retromamillar tissue represents another method to safely excise the tumor in combination with reduction mammoplasty. Also after oncoplastic surgery, the breast has to undergo postoperative radiotherapy.

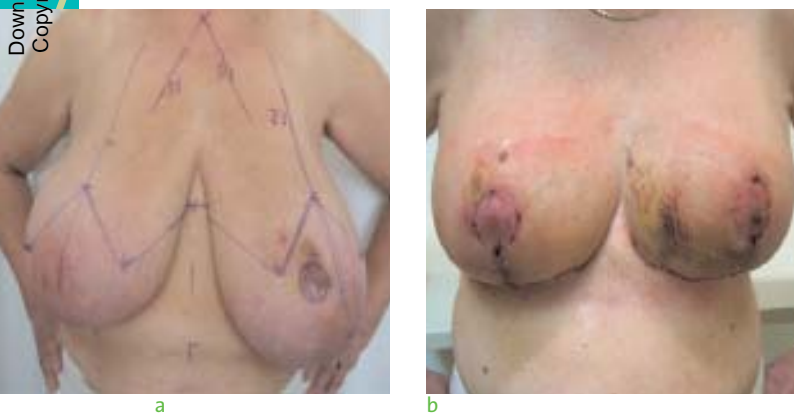


Figure 4: Oncoplastic surgery: preoperative marking (a) and postoperative results (b)

### Breast conserving therapy after neoadjuvant chemotherapy

Preoperative systemic therapy is as effective as postoperative adjuvant chemotherapy of a similar kind. Neoadjuvant chemotherapy enables surgery of primarily inoperable tumors. However, especially the rate of breast conserving surgery of larger tumors can be increased. Prior to preoperative systemic therapy, position and size of the tumor have got to be precisely defined, documented with imaging guidance and marked with clips in the course of the core biopsy in order to safely perform the surgery referring to the oncological criteria, especially in the case of a good regression of the tumor. Also in the case of a clinically complete remission, tumor cells can remain in the former periphery of the tumor (Fig. 5). Extirpation has to be carried out in healthy tissue. Currently, a possibly increased local recurrence rate is still being discussed. However, so far the results of the most extensive study on this topic (NSABP-B18) has not proven positive after an observation period of nine years (Wohlmark et al. 2001).

#### Partial remission

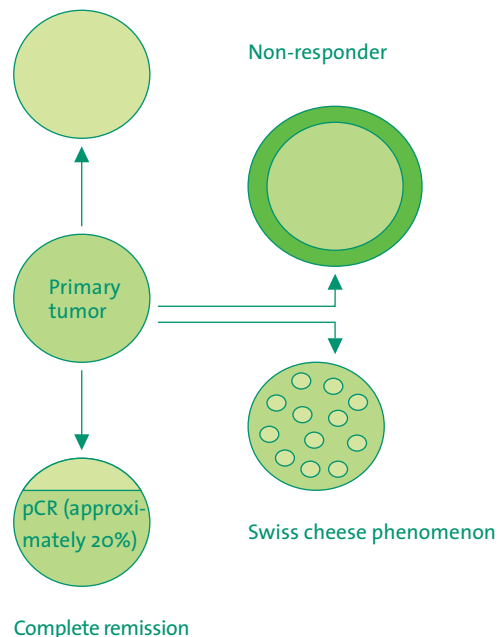


Figure 5: The different alterations of the tumors under neoadjuvant chemotherapy

Surgery should take place approximately one week after the nadir. Only in case of progressing cancer should surgery be prescheduled after two to three cycles. In non-responders (“stable disease”), the standard full does chemotherapy is recommended, without an indication for postoperative chemotherapy.

Patients who have an adjuvant indication for chemotherapy should be advised to undergo preoperative systemic therapy. It is known that the complete histological remission (pathological complete remission, pCR) after preoperative systemic therapy is associated with a high overall survival rate. In addition, this would increase the rate of breast conserving therapy.

### Ablative surgery techniques

Indications for ablative surgery are (S3 guidelines, Kreienberg et al. 2008):

- Multicentricity (distance between the tumors > 4 cm)
- Inflammatory disease
- Extensive DCIS (> 4-5 cm)
- Diffusely abnormal mammogram
- Large tumor-breast ratio
- Re-excision for positive margin
- Contraindications for postoperative radiation after breast conserving therapy
- Patient's desire

If breast conserving therapy is contraindicated from an oncological point of view or if the patient does not approve of this treatment, ablative surgery techniques apply. However, the patient has got to be informed about the possibilities of breast reconstruction while planning the operation.

### Modified radical mastectomy (MRM)

MRM (Fig. 6) includes the removal of gland, the skin, the nipple areola complex and the pectoralis major fascia. The pectoralis muscles itself are preserved. If the tumor infiltrates the pectoralis fascia, the muscle has to be removed, at least partially. The incision should be horizontal or diagonal and allow for later reconstruction. Performing an MRM while leaving the surrounding soft tissue movable and avoiding disturbing wrinkles or contractions is especially complicated in obese patients with macromastia.

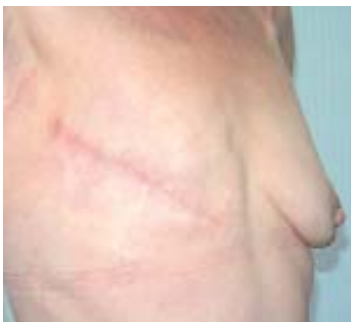

Figure 6: Modified radical mastectomy: postoperative result

### Skin sparing mastectomy (SSM)

Another ablative surgery technique is SSM. Here, the gland and the nipple areola complex are removed. In contrast to the classical MRM, the skin mainly remains intact (Fig. 7), which enables the immediate reconstruction, the prerequisite for the SSM procedure. This procedure preserves the skin and particularly the inframammary fold. Also the sensitivity of the breast remains partially intact.

Oncological safety is provided in SSM if the complete mammary gland is removed. However, this is only possible if dissection takes place ventral of the suspensory ligaments of the mammary gland, whereby leaving the subcutaneous fat and the skin intact. Under these circumstances, SSM is also indicated in extensive suspicious microcalcifications/DCIS. The discussion on whether conservation of the nipple areola complex is possible is currently being investigated. So far, no data are available which would allow for a recommendation.

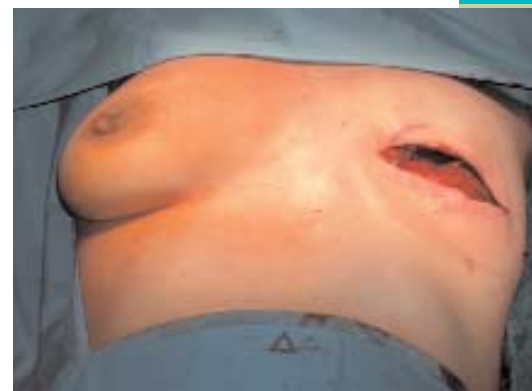

Figure 7: Skin sparing mastectomy (SSM)

### Reconstructive surgery techniques

Breast ablation leaves an unacceptable deformity and, for most patients, represents a psychological burden with a considerable impact on their quality of life. Thus, it is important to early and repeatedly inform the patient about the various possibilities of breast reconstruction. If reconstruction is not possible in the institution, the patient has got to be informed about the possibility of a referral to a different clinic.

Reconstruction of the breast can be performed simultaneously with the mastectomy (immediate reconstruction) or be performed in a second surgery in a so-called delayed breast reconstruction. When considering immediate reconstruction in a patient, the indication for postoperative irradiation has to be taken into account, as this greatly worsens the result of the reconstruction. As the rate of postoperative irradiation of the thoracic wall has increased, immediate reconstruction is only rarely carried out

nowadays. In delayed breast reconstruction, the breast is reconstructed only after completion of adjuvant therapy. If irradiation of the thoracic wall was carried out, the interval between radiotherapy and reconstructive surgery should be at least 10 to 12 months. Due to the fibrosis and the reduced elasticity of the irradiated tissue, reconstruction following radiation of the thoracic wall by tissue expansion and prosthesis is only possible in individual cases. Prerequisites are an appropriate amount of soft tissue and a sufficiently informed patient. An alternative is breast reconstruction with autogenous tissue in combination with an implant.

### Reconstruction with alloplastic material

In most cases, the first step is the implantation of a tissue expander (Fig. 8) in the submuscular pocket of the pectorales muscles, serratus anterior muscle, obliquus externus muscle and rectus abdominis muscle. Another option is the use of acellular dermal matrix. The expander is necessary in order to stretch the remaining skin and thus achieve a degree of ptosis equivalent to the contralateral side. The expander is inflated gradually twice a week with 20 ml to 40 ml saline solution. In a second operation approximately six months later, the expander port is removed if the expander remains as the permanent prosthesis or the expander is replaced by a permanent prosthesis. The construction with implants is less strenuous in contrast to the flap reconstruction. However, it involves several interventions due to implant exchange, correction of the inframammary fold, adjustments of the contralateral side as well as of the unnatural breast consistency. Further disadvantages of this procedure are the occasionally unsatisfactory cosmetic results due to the absence of ptosis, development of capsula fibrosis and dislocation of the prosthesis.

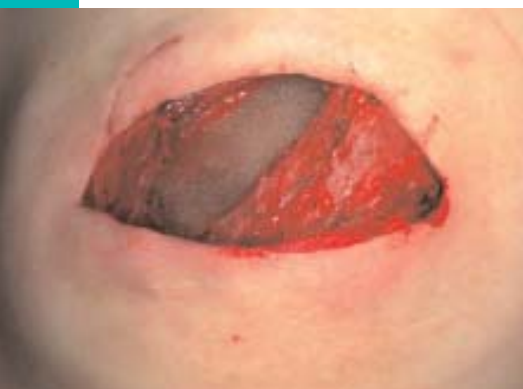

Figure 8: subpectoral tissue expander

### Autogenous breast reconstruction

The reconstruction of the breast mould with skin-muscle flaps (Fig. 9) is increasingly preferred compared to implant techniques, even though prospective randomized studies that prove the advantages do not exist to date. In most cases, the cosmetic results range between good to very good. Disadvantages are the time consumption and the increased burden for the patient. The autogenous tissue is usually taken from the back or the lower abdominal wall.

In the case of small breasts, the volume of the latissimus dorsi muscle in combination with a big skin island flap, which is partly de-epithelialized, can provide enough tissue bulk for breast reconstruction, as the muscle is usually covered by subcutaneous fat. In the course of time, however, the muscle suffers from atrophy which causes a structural and size asymmetria, making correcting procedures necessary. Thus, the additional insertion of a prosthesis can become necessary in order to achieve a sufficient volume of the breast. The wide latissimus dorsi muscle including the skin islet (Fig. 9b) is especially suitable for coating the implant. However, the scars in the back can become disturbing due to the occurring tensions and thus require correction.

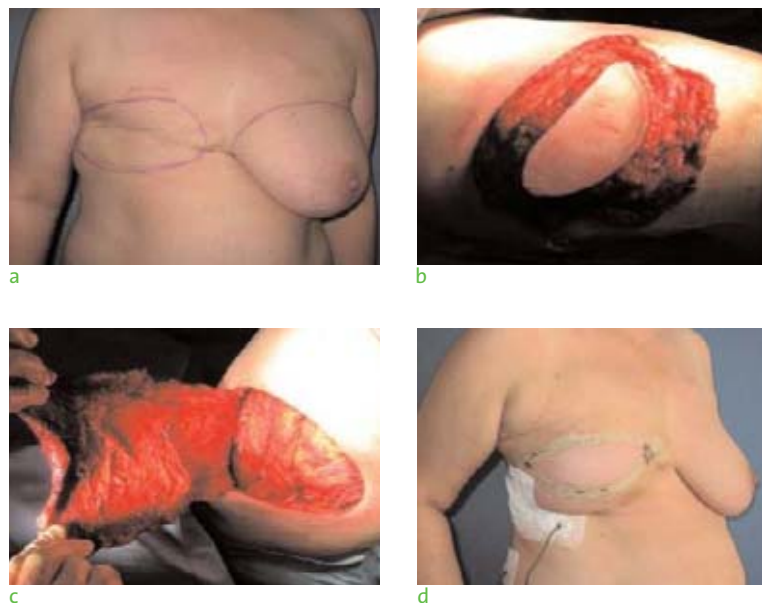


Figure 9: Latissimus-dorsi flap: preoperative signs (a); preparation of the lobe with skin islet (b); mobilization of the lobe (c); postoperative result prior to compensating reduction mammoplasty left (d)

The transverse rectus abdominis myocutaneous (TRAM) flap technique has considerably improved breast reconstruction. Below the umbilicus, there is usually enough tissue to reconstruct the breast solely from autogenous tissue (Fig. 10, 11). With the help of a TRAM, it is often possible to reconstruct shape, size and consistency of the contralateral breast. Contraindications for TRAM flap reconstruction are

smoking, severe obesity, inadequate excess abdominal tissue, and abdominal incisions from previous surgeries.

A variation of the double-sided method of the inaugurator C. R. Hartrampf (Hartrampf et al. 1982) is the pedicled flap procedure, in which parts of the rectus abdominis muscle are preserved. Here, one side of the rectus muscle is completely detached from the fascial sheaths apart from the remaining lateral third. The fascia completely remains in situ, which enables its complete closure. This technique reduces the debilitation of the abdominal wall and thus the risk to develop hernias.

In order to further reduce morbidity in the abdominal wall area, the free TRAM flap as well as the perforator flap (DIEP: "deep inferior epigastric perforator") have been developed. In the free TRAM flap procedure, only a small muscle segment of the rectus is removed, in case of the perforator lobe, the rectal muscles remain intact. This has a positive effect on the stability of the anterior abdominal wall and minimizes the postoperative abdominal wall hernias. Prerequisite for this surgery technique is an experienced surgeon with microsurgical competence, as in both techniques, the reconnection of the blood vessels requires microsurgical surgery.

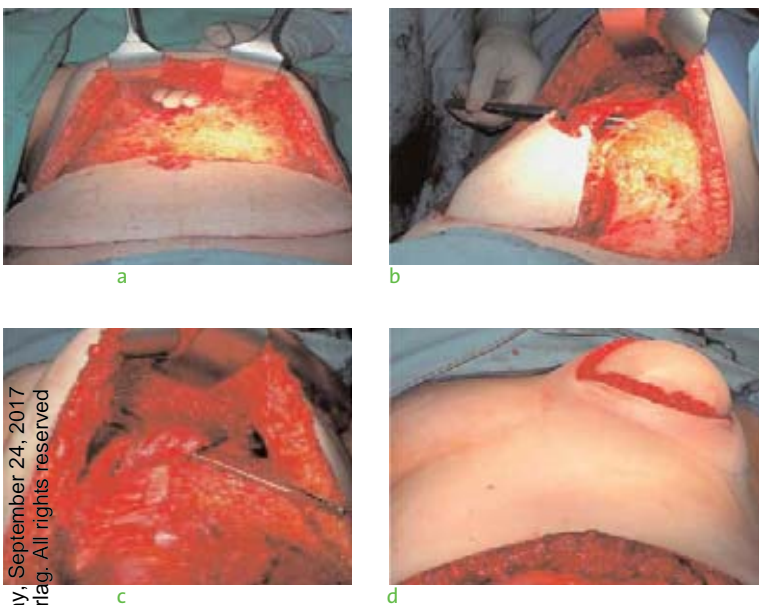


Figure 10: TRAM-procedure: Tunnel construction following flap mobilization (a); right rectus abdominis muscle with flap (b); flap rotated into the wound (c); rotated flap in reconstructed breast (d)

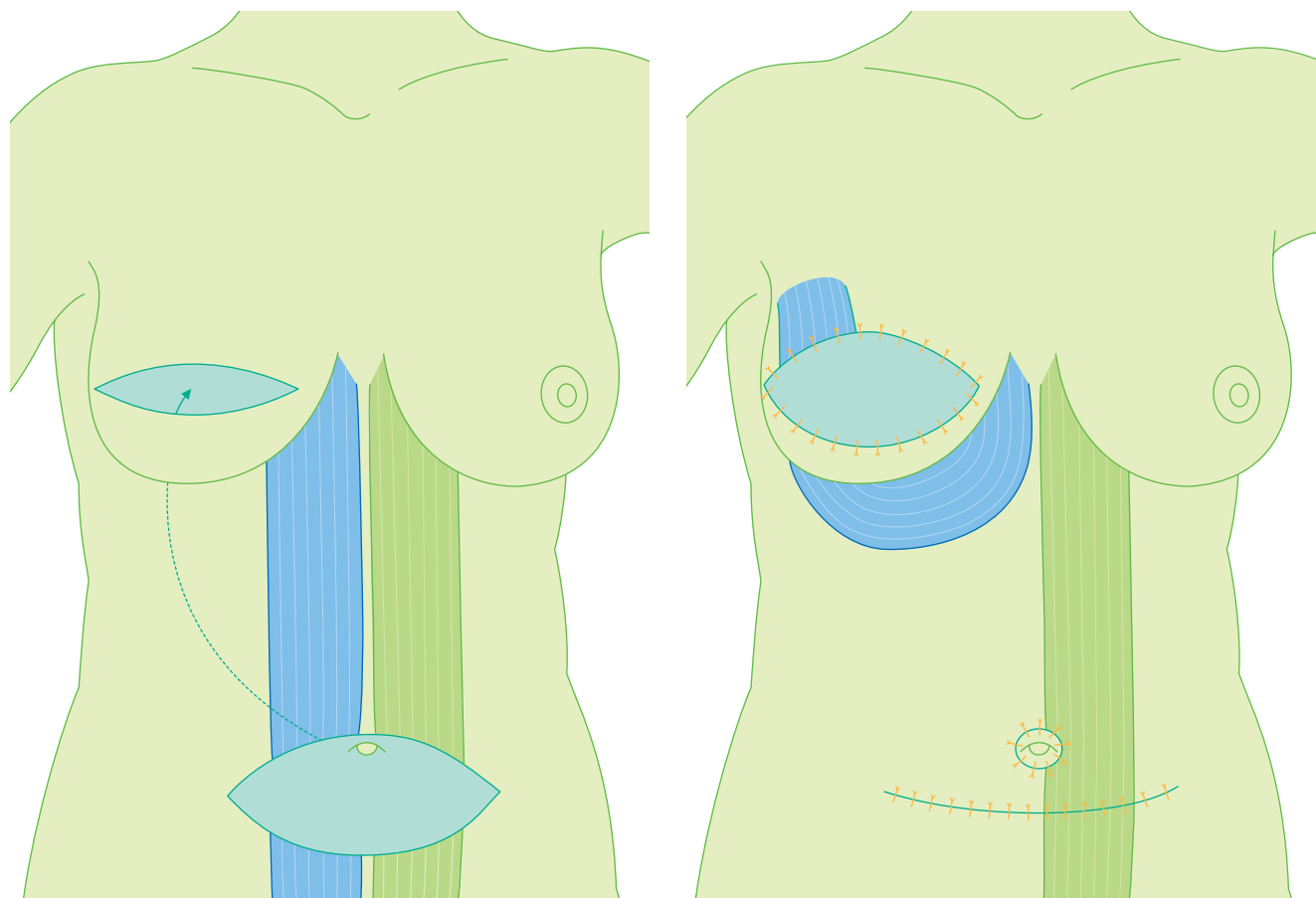


Figure 11: Simplified graphical representation of breast reconstruction with a TRAM flap procedure

The greatest disadvantage of the different TRAM surgeries is the danger of a partial or complete flap failure. In case of the unipedicled TRAM procedure, the risk for flap failure is only 1%. However, partial flap failure and adipose tissue necrosis is far more common with a risk of 10% to 25% (Baldwin et al. 1994; Nahabedian 2004). In high-risk patients, TRAM flap delay before flap transfer is recommended. This two-stage procedure improves perfusion of the flap. One to four weeks prior to the TRAM flap procedure, the superior and the inferior epigastric vessels are ligated, accessed from an inferior flap incision down the fascia.

The failure rate of the free TRAM and DIEP flaps (no microvascular surgery) is 4% (Banic et al. 1995; Nahabedian 2004). In addition, in 15% of surgeries, the revision of the vascular anastomosis has got to be expected (Banic et al. 1995; Guerra et al. 2004).

As in Germany only an average of ten teams perform more than ten DIEP surgeries per year (Blohmer 2009), this method remains restricted to particular indications. In contrast, the pedicled TRAM procedure is part of routine surgery in several centers. However, the free TRAM flap procedure should today be included in the preoperative information of the patient.

### Nipple and areola reconstruction

Reconstruction of the nipple areola complex is an essential and defining component of the breast aesthetics but should only be carried out once breast reconstruction has been completed. The position of the nipple and areola has to be precisely planned in accordance with the patient in the standing position facing a mirror.

Preferential surgery techniques for nipple areola complex reconstruction include:

- Nipple sharing
- Skate flap purse-string technique
- Hammond flap

The contralateral mamilla can be parted horizontally or vertically. The skin in the donor area is reapproximated with a subcuticular monocryl stitch (5-0). The recipient area is de-epithelialized in a small area, on which the pedicled nipple is fixated with metric simple interrupted stitch (5-0).

After sketching the areola area, wing-like skin parts are prepared for the skate flap and the Hammond flap techniques, which are adapted at 6 o'clock with metric simple interrupted stitches (5-0). While in the skate technique, free skin transplantation is necessary, the hammond flap only leaves a horizontal scar with a length that corresponds to that of the future areola. The areola can then easily be

reconstructed as an intradermal tattoo without skin transplantation. This type of areola reconstruction is also applied in the nipple sharing technique (Fig. 12).



Figure 12: Newly reconstructed nipple: postoperative result

### Axillary lymph node dissection

Histology in order to determine the status of the regional lymph nodes (Fig. 13) is part of the surgical procedure in invasive breast cancer. The conventional axillary lymphoidectomy goes along with severe acute and chronic morbidity (Engel et al. 2003; Veronesi et al. 2003). To a great extent, sentinel lymph node biopsy (Fig. 14 and 15) has now substituted conventional axillary dissection. The procedure allows the identification of nodal negative patients, who do not require further local therapy in the lymph drainage area. Until now, only women with T1 and T2 tumors were suitable for sentinel lymph node biopsy. However, recent investigations could show that the diagnostic safety is also given in larger tumors (Kuehn et al. 2005; Lyman et al. 2005), multicentricity or extensive multifocal disease (Gentillini et al. 2006) as well as after smaller excision biopsies (Kuehn et al. 2005; Lyman et al. 2005). Currently, physicians are encouraged to perform SLNB prior to neoadjuvant chemotherapy in clinical trials (SENTINA study; Kuehn et al. 2005; Lyman et al. 2005).

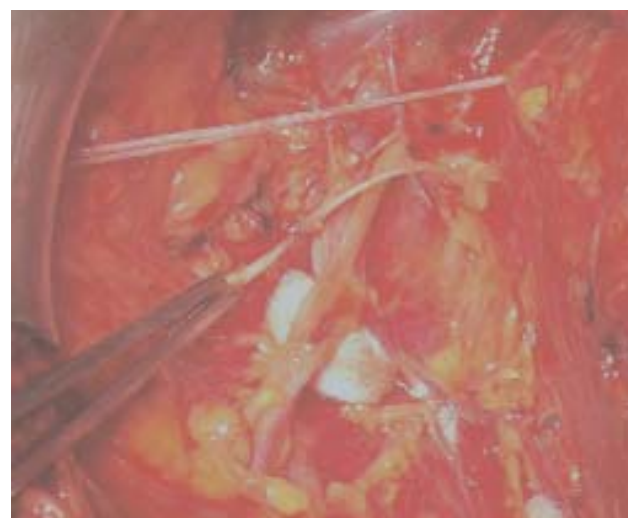


Figure 13: Orientating structures in the axillary region

Sentinel lymph node biopsy is contraindicated in clinical suspicion of advanced lymph node involvement as well as in inflammatory carcinoma. In those cases, at least ten lymph nodes from level 1 and 2 should be removed for the clarification of the nodal status. If this confirms the suspicion, a complete axillary lymphoidectomy is indicated in order to achieve local tumor control. If macrometastases or micrometastases (pN1 (sn) or pN1 mic (sn)) are present, a conventional lymph node excision has got to be carried out. In contrast, the occurrence of isolated tumor cells in the sentinel lymph node (sn(i+)) is no indication for lymph node excision.

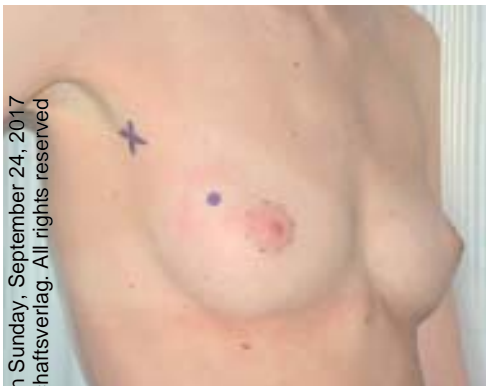

Figure 14: SLNB: periaortic application of technetium

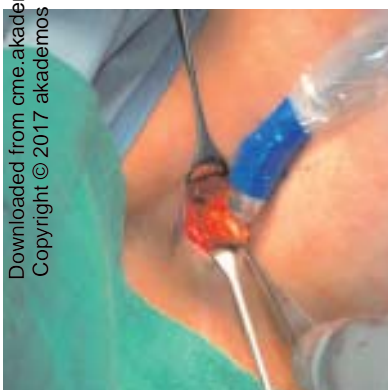

Figure 15: intraoperative sentinel lymph node presentation

CME Prakt Fortbild Gynakol Geburtsmed Gynakol Endokrinol 2009; 5(2): 138-147

#### Keywords

Breast cancer, surgical treatment, breast conserving therapy, mastectomy, reconstruction

#### References

- BALDWIN BJ, SCHUSTERMAN MA, MILLER MJ, KROLL SS, WANG BG.** Bilateral breast reconstruction: conventional versus free TRAM. *Plast Reconstr Surg* 1994; 93: 1410–16.
- BANIC A, BOECKX W, GREULICH M, GUELICKX P, MARCHI A, RIGOTTI G, TSCHOPP H.** Late results of breast reconstruction with free TRAM flaps. A prospective multicentric study. *Plast Reconstr Surg* 1995; 95: 1195–204.
- BLOHMER JU.** Persönliche Mitteilung; 2009.
- VAN DONGEN JA, VOOGD AC, FENTIMAN IS, LEGRAND C, SYLVESTER RJ, TONG D, VAN DER SCHUEREN E, HELLE PA, VAN ZIJL K, BARTELINK H.** Long-term results of a randomized trial comparing breast-conserving therapy with mastectomy: European Organization for Research and Treatment of Cancer 10801 Trial. *J Natl Cancer Inst* 2000; 92: 1143–50.
- ENGEL J, KERR J, SCHLESINGER-RAAB A, SAUER H, HÖLZEL D.** Axilla surgery severely affects quality of life: results of a 5-year prospective study in breast cancer patients. *Breast Cancer Res Treat* 2003; 79: 47–57.
- FISHER B, ANDERSON S, BRYANT J, MARGOLESE RG, DEUTSCH M, FISHER ER, JEONG JH, WOLMARK N.** Twenty-year follow-up of a randomized trial comparing total mastectomy, lumpectomy and lumpectomy plus irradiation for the treatment of invasive breast cancer. *N Engl J Med* 2002; 347: 1233–41.
- GENTILINI O, TRIFIRÒ G, SOTELDO J, LUINI A, INTRA M, GALIMBERTI V, VERONESI P, SILVA L, GANDINI S, PAGANELLI G, VERONESI U.** Sentinel lymph node biopsy in multicentric breast cancer. The experience of the European Institute of Oncology. *Eur J Surg Oncol* 2006; 32: 507–10.
- GERBER B, KRAUSE A, REIMER T, MÜLLER H, FRIESE K.** Breast reconstruction with latissimus dorsi flap. *Plast Reconstr Surg* 1999; 103(7): 1876–81.
- GUERRA AB, METZINGER SE, BIDROS RS, RIZZUTO RP, GILL PS, NGUYEN AH, DUPIN CL, ALLEN RJ.** Bilateral breast reconstruction with deep inferior epigastric perforator (DIEP) flap: an experience with 280 flaps. *Ann Plast Surg* 2004; 52: 240–52.
- HARTRAMPF CR JR, SCHEFLAN M, BLACK PW.** Breast Reconstruction with a Transverse Abdominal Island Flap. *Plast Reconstr Surg* 1982; 69: 216.
- HELLMANN S.** Stopping metastases at their source. *N Engl J Med* 1997; 337: 996–97.
- HÖLZEL D, ENGEL J, SCHMIDT M, SAUER H.** A model for primary and secondary metastasis in breast cancer and clinical consequences. *Strahlenther Onkol* 2001; 177: 10–24.
- KOSCIELNY S, TUBIANA M.** The link between local recurrence and distant metastasis in human breast cancer. *Int J Radiation Oncology Biol Phys* 1999; 43: 11–24.



**KUEHN T, BEMBENEK A, DECKER T, MUNZ DL, SAUTTER-BIHL ML, UNTCH M, WALLWIENER D; CONSENSUS COMMITTEE OF THE GERMAN SOCIETY OF SENOLOGY.** A concept for the clinical implementation of sentinel lymph node biopsy in patients with breast carcinoma with special regard to quality assurance. *Cancer* 2005; 103: 451–61.

**KREIENBERG R, KOPP I, ALBERT U, BARTSCH HH ET AL. (HRSG).** Interdisziplinäre S3-Leitlinie für Diagnostik, Therapie und Nachsorge des Mammakarzinoms. Germering/München: Zuckschwerdt 2008.

**LYMAN GH, GIULIANO AE, SOMERFIELD MR, BENSON AB 3<sup>RD</sup>, BODURKA DC, BURSTEIN HJ, COCHRAN AJ, CODY HS 3<sup>RD</sup>, EDGE SB, GALPER S, HAYMAN JA, KIM TY, PERKINS CL, PODOLOFF DA, SIVASUBRAMANIAM VH, TURNER RR, WAHL R, WEAVER DL, WOLFF AC, WINER EP; AMERICAN SOCIETY OF CLINICAL ONCOLOGY.** American Society of Clinical Oncology guideline recommendations for sentinel lymph node biopsy in early-stage breast cancer. *J Clin Oncol* 2005; 23: 7703–20.

**NAHABEDIAN MY.** Defining the »Gold Standard« in breast reconstruction with abdominal tissue. *Plast Reconstr Surg* 2004; 114: 804–10.

**VERONESI U, CASCINELLI N, MARIANI L, GRECO M, SACCOZZI R, LUINI A, AGUILAR M, MARUBINI E.** Twenty-year follow-up a randomized study comparing breast-conserving surgery with radical mastectomy for early breast cancer. *N Engl J Med* 2002; 347: 1227–32.

**VERONESI U, PAGANELLI G, VIALE G, LUINI A, ZURRIDA S, GALIMBERTI V, INTRA M, VERONESI P, ROBERTSON C, MAISONNEUVE P, RENNE G, DE CICCIO C, DE LUCIA F, GENNARI R.** A randomized comparison of sentinel-node biopsy with routine axillary dissection in breast cancer. *N Engl J Med* 2003; 349(6): 546–53.

**WOLMARK N, WANG J, MAMOUNAS E, BRYANT J, FISHER B.** Preoperative chemotherapy in patients with operable breast cancer: nine-year results from NSABP-B18. *Natl Cancer Inst Monogr* 2001; 30: 96–102.



Dipl. med. Fakher Ismaeél

Klinik für Frauenheilkunde und Geburtshilfe  
Charité – Universitätsmedizin Berlin  
Campus Virchow-Klinikum  
Augustenburger Platz 1  
13353 Berlin  
Germany

Mr. Fakher Ismaeél studied medicine at the Medical University of Aden. He completed his specialization at the gynecologic and obstetric clinic “DRK Kliniken Berlin, Köpenick”. Until 2008, he was senior physician and vice chief physician. Since 2008, he has been working as senior physician in the gynecologic department of the “Charité Berlin, Campus Virchow-Klinikum”. His main focus is on senology and oncologic gynecology.

#### Conflict of interest

The author declares that there is no conflict of interest as defined by the guidelines of the International Committee of Medical Journal Editors (ICMJE; [www.icmje.org](http://www.icmje.org)).

#### Manuscript information

Submitted on: 01.03.2009

Accepted on: 27.04.2009

# CME-Continuing Medical Education

## Surgical treatment of breast cancer

### Question 1

In Germany, how many patients per year develop breast cancer?

- a. approximately 8000
- b. approximately 25000
- c. approximately 30000
- d. approximately 55000
- e. approximately 15000

### Question 2

Which of the following is the most common gynecologic malignant tumor?

- a. Ovarian cancer
- b. Vulvar cancer
- c. Breast cancer
- d. Endometrial cancer
- e. Cervical cancer

### Question 3

For invasive breast cancer, the S3 guidelines of the "Deutsche Krebsgesellschaft" (German Cancer foundation) and the DGGG recommend tumor excision with a safety margin of:

- a. 10 mm
- b. 5 mm
- c. > 10 mm
- d. > 5 mm
- e. 1 mm

### Question 4

For the ductal carcinoma in situ (DCIS), the S3 guidelines of the "Deutsche Krebsgesellschaft" (German Cancer foundation) and the DGGG recommend tumor excision with a safety margin of:

- a. 5 mm
- b. 10 mm
- c. 1 mm
- d. > 10 mm
- e. > 15 mm

### Question 5

When is breast conserving therapy contraindicated?

- a. in locally confined DCIS
- b. in invasive carcinoma with a large tumor-breast ratio
- c. in inflammatory disease
- d. in DCIS < 4 cm
- e. in case of suspicious microcalcifications in one breast quadrant

### Question 6

When is breast ablation *not* indicated?

- a. in multicentric carcinoma
- b. in DCIS > 4-5 cm
- c. in the presence of contraindications for postoperative radiation after breast conserving therapy
- d. in locally confined DCIS
- e. in cases of a large tumor-breast ratio

### Question 7

The flap failure rate in TRAM or DIEP flaps (including microvascular loss) is approximately:

- a. 20%
- b. 4%
- c. 10%
- d. <4%
- e. 15%

### Question 8

How many lymph nodes should be excised in a conventional lymphoidectomy?

- a. < 10 lymph nodes
- b. > 20 lymph nodes
- c. lymphoidectomy level 1 to 3
- d. 10 lymph nodes
- e. only enlarged, abnormal lymph nodes

### Question 9

Sentinel lymph nodes biopsy is contraindicated in:

- a. tumors larger than T1 and T2
- b. multifocal lesions
- c. multicentricity
- d. before neoadjuvant chemotherapy
- e. clinically suspicious axillary lymph nodes and inflammatory disease

### Question 10

How long after thoracic irradiation can secondary reconstruction commence?

- a. 6 months
- b. 3 years
- c. 10-12 months
- d. no reconstruction after irradiation
- e. immediately after completion of radiotherapy

## Impressum

Herausgeber  
Pränataldiagnostik und Geburtsmedizin  
Priv.-Doz. Dr. med. Kai J. Bühling  
Universitätsfrauenklinik Hamburg-Eppendorf  
Martinistr. 52  
D-20246 Hamburg  
Telefon 040 428032540  
E-Mail: [kjbuehling@aol.com](mailto:kjbuehling@aol.com)

Endokrinologie und Reproduktionsmedizin  
Dr. med. Andreas Jantke  
Gemeinschaftspraxis FERA  
im Wenckebach-Klinikum  
Wenckebachstr. 23  
D-12099 Berlin  
Telefon 030 76007011  
Telefax 030 76007014  
[www.fera-berlin.de](http://www.fera-berlin.de)

Gynäkologie und Gynäkologische Onkologie  
Prof. Dr. med. Jalid Sehouli  
Charité – Universitätsmedizin Berlin  
Klinik für Frauenheilkunde und Geburtshilfe  
Augustenburger Platz 1  
D-13353 Berlin  
Telefon 030 450564043  
Telefax 030 450564902  
E-Mail: [sehouli@aol.com](mailto:sehouli@aol.com)

## Verlag

akademos Wissenschaftsverlag GmbH  
Strindbergweg 57  
D-22587 Hamburg  
Telefon 040 88941973  
Telefax 040 88941980  
[www.akademos.de](http://www.akademos.de)

## Auflage

Gesamtauflage 15.000

## Abonnement

CME Praktische Fortbildung Gynäkologie, Geburtsmedizin und Gynäkologische Endokrinologie erscheint dreimal jährlich. Der Bezug dieser Zeitschrift ist für Abonnenten kostenlos. Interessenten, die noch keine Zeitschrift erhalten, können diese unter [www.akademos.de/gyn](http://www.akademos.de/gyn) nach Registrierung abonnieren. Eine Abbestellung ist jederzeit möglich. Sämtliche Inhalte sind nach Registrierung auch online unter [www.akademos.de/gyn](http://www.akademos.de/gyn) kostenlos erhältlich.

Nachbestellungen können aufgegeben werden bei der Leipziger Kommissions- und Großbuchhandelsgesellschaft (LKG)  
Pötzschauer Weg  
04579 Espenhain  
Telefon 034206 65224  
Telefax 034206 651733

Der Preis für eine nachträglich bestellte Ausgabe beträgt Euro 10,- inkl. MwSt. und Versand.



## CME-Zertifizierung

Die Zertifizierungspunkte werden von der Ärztekammer Berlin vergeben. Diese Zertifizierung wird nach § 11 der (Muster-)Satzungsregelung Fortbildung und Fortbildungszertifikat von allen anderen Ärztekammern anerkannt.



## Anerkannt von der Österreichischen Ärztekammer

([www.arztakademie.at/dfp](http://www.arztakademie.at/dfp))

§ 26 (3) DFP Richtlinie – Approbation ausländischer Veranstaltungen  
»Die von der EACCME (European Accreditation Council for Continuing Medical Education der Union European Medical Specialists [UEMS]) anerkannten CME Credit Points sowie von deutschen Landesärztekammern anerkannte Fortbildungspunkte der Kategorie A, B und D werden als DFP-Punkte bzw. DFP-Fachpunkte anerkannt. Der Arzt nimmt die Zuordnung zum Fachgebiet entsprechend der DFP-Systematik selbst vor.«

## Rechtliches

### Copyright

Dieses Werk, einschließlich aller seiner Teile, ist urheberrechtlich geschützt. Die dadurch begründeten Rechte, insbesondere die der Vervielfältigung, der Übersetzung, der Entnahme von Abbildungen und Tabellen, der Veröffentlichung sowie der Speicherung und Verarbeitung durch Datenverarbeitungsanlagen, bleiben vorbehalten. Sie bedürfen des schriftlichen Einverständnisses des Verlages. Zuwiderhandlungen unterliegen den Strafbestimmungen des Urheberrechtsgesetzes.

### Warenzeichen

In dieser Zeitschrift sind die Stichwörter, die zugleich eingetragene Warenzeichen darstellen, als solche nicht besonders kenntlich gemacht. Es kann demnach aus der Bezeichnung der Ware mit dem für diese eingetragenen Warenzeichen nicht geschlossen werden, dass die Bezeichnung ein freier Warenname ist.

### Haftungsausschluss

Vor der Verwendung eines jeden Medikamentes müssen der zugehörige wissenschaftliche Prospekt und der Beipackzettel mit den Angaben in dieser Zeitschrift verglichen werden. Denn neue Erkenntnisse über Toxizität, Dosierung, Applikationsart und Intervall können jederzeit zu anderen Empfehlungen führen. Außerdem sind neue Resultate aus klinischen Studien nicht direkt auf den klinischen Alltag übertragbar. Ferner sind Druckfehler trotz aller Sorgfalt nicht sicher vermeidbar. Für etwaige inhaltliche Unrichtigkeiten der Zeitschrift übernehmen Herausgeber und Verlag keinerlei Verantwortung oder Haftung. Jede Dosierung oder Applikation erfolgt auf eigene Gefahr des Benutzers. Für unverlangt eingesandte Manuskripte übernimmt der Verlag keine Haftung.

V.i.S.d.P.: Priv.-Doz. Dr. Kai J. Bühling

## Gestaltung und Satz

bb gestaltung, Berlin und Hamburg

## Lektorat

Martina Kunze

© akademos Wissenschaftsverlag GmbH, Hamburg 2009

[www.akademos.de](http://www.akademos.de)

ISSN 1614-8533