

Pruritus vulvae

Axel Schäfer

Frauenklinik, Campus Virchow-Klinikum,
Charité – Universitätsmedizin Berlin, Berlin

Reviewers: Karen Weißhaupt, Berlin
and Jan-Peter Siedentopf, Berlin

Summary

Pruritus vulvae can have infectious as well as non-infectious causes. In sexually active women, infectious-borne pruritus is mainly caused by vulvovaginal candidiasis. However, also changes in the bacterial flora can cause itching and burning. In persistent and regressing cases, we also have to consider non-infectious dermatoses. Here, the most common disease is lichen sclerosus, not only present in postmenopausal women but already in young women and girls before puberty.

Introduction

At first sight, the range of diseases that cause vulvar pruritus seems manageable (Table 1). From our experience, we know that the most common cause for vulvar pruritus is a fungal infection; or else an itching non-infectious dermatosis, most likely a dystrophy such as lichen sclerosus. However, problems arise when various symptoms coexist. Either several diseases are present or the symptoms alter between pruritus and burning. Pain maybe persistent or occur only during or after sexual intercourse. Very often, the severity of the individual symptoms differs; thus, the patient cannot tell exactly whether she feels more pruritus, burning or pain. These circumstances may complicate the process of making the correct symptom-oriented diagnosis, especially if the symptoms do not improve albeit several therapeutic interventions. Consequently, the medications get more and more every time. Repeatedly, antimycotics or even antibiotics, lactobacillus preparations and estriol vaginal cream, very often with an additional corticosteroid cream, are prescribed; a rather expensive treatment regimen.

By now, the patient has replaced her gynecologist a number of times, and maybe even undergone psychosomatic therapy. However, her pruritus persists and dominates her life making her present to the outpatient department of a larger hospital. Upon arrival, she places a plastic bag on the table containing all preparations lately prescribed as well as reports from recent visits to the doctor.

Maybe the patient sits opposite to a young assistant doctor in her second last year of specialization (although assistant doctors are very rare these days in our subject), who is obviously surprised about the pile of packages. Alerted by the fact that most packages are brand-new, the assistant doctor might ask whether the patient has used any of them. The patient might answer that she has only partly tried taking the prescribed drugs because none of them improved her condition and some even worsened her symptoms and caused burning.

Women with vulvar chronic and recurrent pruritus often haven't suffered greatly, most likely comparable to women with chronic lower pelvic pain. In general, complaints in the vulvar region are common, as the area is sensitive and associated with sexuality. Table 1 summarizes the possible causes for pruritus and divides them into three categories: infectious, non-infectious inflammatory dermatoses and other causes.

The second column in Table 1 lists those diseases that become apparent with burning pain. When making a clinical diagnosis, it is important that some diseases cause pruritus as well as burning. Lichen sclerosus, for example, most commonly causes pruritus. However, if continuous scratching slows the healing process, erosions get superinfected and burning will develop additionally. Vulvovaginal fungal infections will cause pruritus, although not every detected fungus implies a symptomatic mycosis. *Candida spp.*, however, are typical opportunists. They take advantage of conditions that disrupt the balance of the normal vaginal flora, of moist areas as well as of skin lesions.

Changes in the normal vaginal flora and irritation of the vulva are always present in bacterial vaginitis. Apart from candidiasis, the bacterial infection can promote other pathogens. Thus, both a bacterial and a mycotic infection can coexist. Similarly, lesions in lichen sclerosus may be superinfected with *Candida spp.*, i.e. there are two causes for the pruritus, a fact that has got to be considered for a successful therapeutic strategy.

Table 1: Symptoms of vulvar and vulvovaginal diseases

Pruritus	Burning/pain
Infections	Infections
Vulvovaginal candidiasis	Bacterial vaginosis
Dermatophytosis	Trichomoniasis, Herpes simplex, Herpes zoster
Parasites: • Scabies (especially <i>Sarcoptes scabiei hominis</i>) • <i>Phthirus pubis</i> • Anal helminth infections (<i>Oxyuris vermicularis</i> syn. <i>Enterobius vermicularis</i>)	Bacterial folliculitis Abscess formation (<i>Staphylococcus aureus</i>) Pyoderma (Group A Streptococcus)
Predisposition for mycoses due to diabetes mellitus, liver diseases, immunosuppression	Aerobic bacterial vaginitis Vulvitis plasmacellularis
Other causes	Other causes
Regrowth of pubic hair after shaving	Injuries, focal vulvitis Vulvodynia
Psychogenic causes and sexual disorders	Psychogenic causes and sexual disorders
Malignancies	Malignancies
Non-infectious or inflammatory diseases of the vulva	Non-infectious or inflammatory diseases of the vulva
Lichen sclerosus	Lichen sclerosus with erosions from scratching
Mucosal lichen planus	Erosive lichen planus
Lichen simplex chronicus	Contact irritant dermatitis
Contact dermatitis	Allergic contact dermatitis
Drug-related exanthema	Drug-related exanthema
Psoriasis	Pemphigus M. Behçet

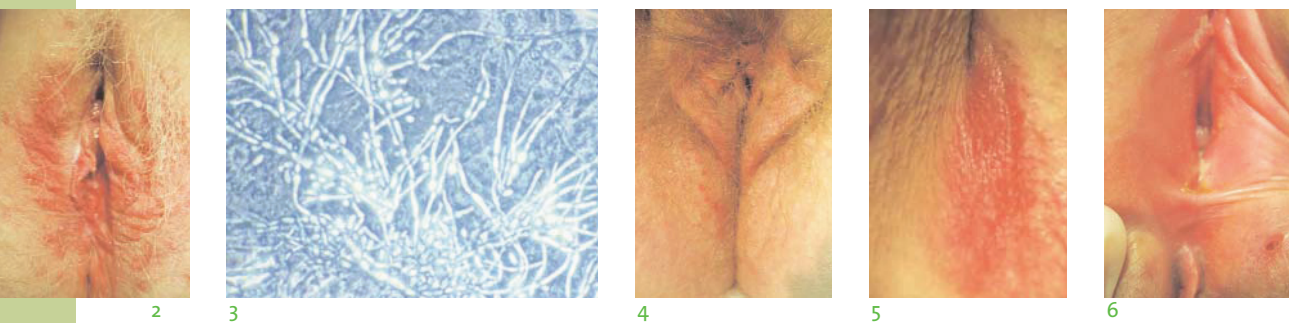


Figure 2: 35-year-old patient with vulvar candidiasis

Figure 3: *Candida pseudohyphae* and germ tubes detected with phase contrast microscopy

Figure 4: 45-year-old patient with vitiligo and lichen sclerosus with a simultaneous follicular candidiasis

Figure 5: Inguinal fold with intertriginous dermatitis

Figure 6: 19-year-old patient with Crohn's disease and recurrent infections

Pruritus and infections

From all infectious causes of pruritus, vulvovaginal candidiasis is most common, especially in young women. The major symptoms and the diagnostic approach in patients with genital infections were already described in an issue of this journal in 2006 (Schäfer 2006). Infections with candida usually cause pruritus and develop quickly. However, candida infections may also be a superinfection, for example of dermatoses, which themselves cause pruritus.

Candida spp. and other dermatophytes usually do not invade areas with a normal resident flora. Thus, conditions predisposing for an infection are lesions that have developed for other reasons (such as diabetes or immunosuppression) and if the biological homeostasis is disturbed, either because of immunosuppression in the genitomuco-sal area or changes and gaps in the bacterial flora. A vaginal yeast infection can be brought on by antibiotics. Under these conditions, the yeasts benefit and may thus be called typical opportunists. However, we have to consider that 20% of all women are colonized by *Candida* in the vulvovaginal area but remain asymptomatic. Hormonal contraceptives predispose for fungal infections.

Apart from pruritus, vulvovaginal infections with *Candida spp.* can also cause burning, dysuria and dyspareunia. Very often, there is an erythema of the introitus, which can expand to the vulva. The vulva may be swollen and a more or less pronounced and dotted erythema (Fig. 2) may develop.

White spots on the epithelium in the vaginal orifice may appear together with a typical white, odorless curd-like appearing discharge. The diagnosis can be made by microscopic evaluation of the vaginal discharge either as a wet mount or a gram preparation. Typical findings are germ tubes and pseudohyphae on the cell surface (Fig. 3) and an increased number of blastospores, although the first is a clear diagnosis of an infection with *Candida albicans*, which is to be expected in 98% of all candida infections. In most cases, the pH of the vagina is physiological. A fungal culture is necessary in inconclusive cases and allows for a precise identification of the candida species with selective media. In recurrent infections, sensitivity testing can be done with cultures in special media. However, also when suspecting a recurrent infection, the focus should not only be on the fungus and its possible resistances. Particularly humid skin areas and other vulvar diseases can be the underlying reason (Fig. 4). Erythema and symptoms in these zones do not always have to be caused by fungi (Fig. 5).

Even if blastospores are visible and the culture is positive, the candida infection might not be the cause of the complaints. Patients can be infected with *Candida spp.* Without suffering from genital pruritus. Thus, a positive fungal culture may indicate a possible fungal infection, but cannot confirm diagnosis. This is also valid for finding fungal spores in the wet mount as well as for the interpretation of cytology screening results.

The treatment of a superficial yeast infection with local antiseptic substances such as Octenidin or staining solutions such as Castellani's paint can be sufficient. Antimycotics such as the polyenes amphotericin B and nystatin as well as ciclopirox can be applied topically due to their minimal absorption. Resistant yeast infections are very rare. Also the azoles such as clotrimazole can be applied topically as an ointment. In severe and especially recurrent mycoses, the administration of fluconazole is recommended, although alternatively itraconazole or terbinafine can be prescribed.

Dermatophytes only rarely cause infections in the vulvar region. As they require keratinized squamous epithelial cells, the infection is always perivulvar and does not affect the introitus. Diagnosis is confirmed by clinical evaluation or microscopic examination for yeast and hyphae found attached to skin scales. The infection is treated with a long-term application of azole-containing ointments or oral triazoles. Referring to Table 1, predispositions for mycoses include diabetes or immunosuppression. For instance, genital and oral mycoses can often be seen in HIV positive patients or in patients who are immunocompromised for other reasons. However, any imbalance in bacterial flora, for example caused by a direct connection to the intestine either as a rectovulvar or rectovaginal fistula secondary to Crohn's diseases can cause bacterial infections and, due to a massive change in bacterial homeostasis, promote the development of mycoses (Fig. 6).

Other infections of the vulva causing pruritus

Nowadays, skin infections with scabies and *Pthyrus pubes* have become rare.

Scabies, also known as acarodermatitis, is an infectious skin disease in humans. Apart from animal mites (transmitted from animals, their original hosts, to men) from the group of *Sarcoptes* and *Dermanyssidae*, scabies in men is usually caused by *Sarcoptes scabiei hominis*.

The female mite makes a 0.2-0.5 mm long serpentine burrow into the stratum corneum of the skin to deposit her eggs for over two months, leaving fecal pellets behind. Six-legged larvae hatch from the eggs and mature into adult animals within one to two weeks. After mating on the skin surface, the females again make their burrows below the surface.

Clinically, depending on the severity of the infection, pruritus is the main complaint. The mites are especially active at night below the warm blanket. Apart from other skin areas, the vulva can become affected due to sexual transmission. In the skin of the affected patients there are 1 cm long tunnels with a visible elevation at the end where the female mite sits. After a few weeks, the mite excrements cause an inflammatory reaction of the skin with severe pruritus. The patient scratches and the lesions become ulcerous. The mite tunnels can often be found in body folds such as the interdigital region of the toes, the axillary folds but also the mamillae, the wrists, or the fingers. In small children, also the face can be affected.

Sometimes, also bacterial superinfections may occur. The scabies mite cannot survive without its host, usually humans, for more than a few days. The mites are transmitted by direct skin contact, i.e. from person-to-person. Especially people in old-people's homes and nursing homes, kindergartens, schools and hospitals are affected. Prolonged body contact and the natural warmth of the bed favor transmission. Thus, the risk for transmission is especially high during sexual intercourse and within families.

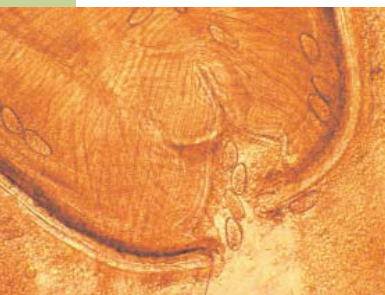
The diagnosis is confirmed by the inspection of the skin, where the 1 cm long burrows are visible. With a magnifying glass or with light microscopy, the burrows, papules and vesicles can be detected. The tunnels can be opened with a scalpel blade, and the material is diluted in 20% potassium hydroxide for one hour. After destruction of the tissue material, the eggs, larvae and mites are visible with the microscope.

Scabies is treated with anti-inflammatory substances such as zinc ointments and, in case of pruritus, topical corticosteroids. Ichthyol ointments and 3% salicylic acid can soften the keratinization process. Available topical scabicides are crotamatin, permethrin, benzyl benzoate and lindane. Clothes and bed linen should be washed at > 60 °C.

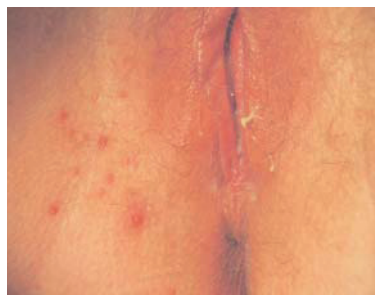In comparison to the head louse, the slightly smaller crab louse *Phthirus pubis* is attached to the pubic hair with their pincher and crawl along them. The females only have a lifespan of a month and lay four to five eggs per day, which they stick to the pubic hair with a water-insoluble substance. The larvae hatch after approximately eight days and within another 18 days, they mature into an adult animal. The crab louse feeds on several blood meals, but can survive without for up to three days.

Clinically, a discomforting pruritus develops and within the scabies lesions, bacterial infections may develop. In addition, a slight reddening and swelling of the hairy parts of the vulva may be present. *Phthirus pubis* is often transmitted sexually. For diagnosis, inspection with colposcopy is recommended. Here, the adult animals or the nymphs are easily detectable in the pubic hair. Possible stray specimens of *Pediculus capitis* can be identified by their greater size.

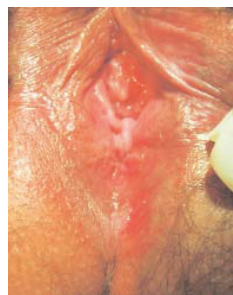The therapy depends on the severity of the infection. If the parasitic load is high, the pubic hair should be shaved, while in mild cases, grooming the hair with a fine-toothed comb can be sufficient. Topical pyrethrum solution, permethrin or coconut oil may be applied topically. Clothes and bed linen should be washed at > 60 °C.



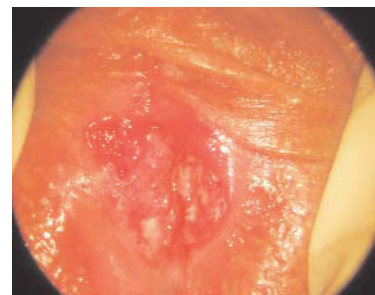7



8



9



10

Figure 7: Pinworm with eggs from a vaginal wet mount

Figure 8: Folliculitis in a 23-year-old patient

Figure 9: 42-year-old patient with pruritus and burning which has persisted for more than a year; carcinoma in situ

Figure 10: 28-year-old patient with a subclitoral carcinoma in situ

Also pinworms or oxyurias (*Oxyuris vermicularis*, syn. *Enterobius vermicularis*) can cause pruritus, especially in and around the anus and at nighttime. Children are more often infected than adults, but the eggs can be transmitted to the mothers or other people. Clinically, the nighttime pruritus and the associated sleeping disorders are more pronounced in children. Other somatic disorders such as abdominal pain and digestive tract disorders are rare. At the time of diagnosis, the 1 cm long adult worms can be seen macroscopically on the stool. As the females lay their eggs especially in the perianal area, transparent adhesive tape can be applied on the anal area and the tape can be examined with a microscope for diagnosis.

Occasionally, the worms go astray from the anus to the vagina. Here, they can cause an inflammatory reaction with vaginal discharge. Figure 7 shows such a worm in a wet mount, which was taken from a mother with several children who suffered from vaginal discharge and vaginal pruritus. Thus, the *Enterobius vermicularis* eggs as a cause of pruritus may even be found in the vaginal smear. The infection is typically treated with mebendazole and pyrantel. However, as relapses are common, treatment should be repeated two to four weeks later.

Other causes

A trivial cause of vaginal pruritus is pruritus caused by hair regrowth. It is very common among young women and girls who have the habit to shave their pubic hair, but are not yet used to shaving. This causes skin irritation, which can sometimes be difficult to assign to the shaving. Frequently, small follicular inflammations occur, which ought to be interpreted as folliculitis (Fig. 8).

In addition, reactions to genital piercings are common. In some cases, there are so many objects that the metal detectors in air traffic control would be activated. Without doubt, psychological or psychosexual disorders or even a pathological fixation on the vulva may play a role here.

However, these aspects would go beyond the scope of this article. In any case, a thorough inspection of the vulvar region is essential. For example, if the patient tells you about a small skin patch that has been itching for weeks or months, particularly when riding her bike. The example in Figure 9 shows an ulceration in the posterior commissure in the bottom right region. A biopsy diagnosed this as a carcinoma in situ, which was then excised in sano.

Figure 10 is an example of a similar patient's history. The 28-year-old patient noticed a small lesion below the clitoris and above the urethra, which causes minimal itching. Two months later, she got concerned and visited her gynecologist, who was alarmed by the nondistinctive ulcer with papillary, spongelike structures. The biopsy revealed a condyloma, VIN I. After excision of the lesion, a carcinoma in situ, which had partly transformed to an invasive carcinoma, was diagnosed.

Non-infectious inflammatory dermatoses

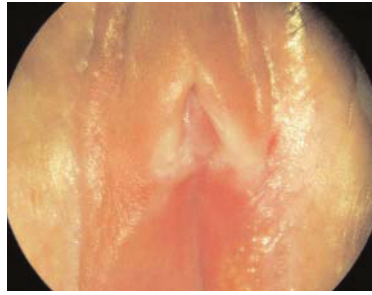Lichen sclerosus

Lichen sclerosus is a rare disease, however, it is the most common non-infectious cause of vaginal pruritus. Girls before the onset of puberty (Fig. 11) as well as adult women, especially in their postmenopausal phase, are affected. As the symptoms of lichen sclerosus decline with puberty, changes in hormonal status such as puberty and pregnancy, are suspected to influence the course of the disease. The accumulation of cases in menopause is also ascribed to changes in the woman's estrogen-androgen and cortisol balance. Stress and traumata can worsen the symptoms.



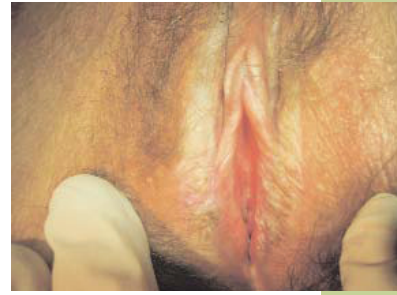11

Figure 11: Predominantly perianal lichen sclerosus in a five-year-old girl (Photo: practice Denmark)



12

Figure 12: 25-year-old patient with histologically confirmed lichen sclerosus but asymptomatic



13

Figure 13: Lichen sclerosus in a 37-year-old woman

Lichen sclerosus is a chronic, progressive inflammation of the connective tissue of the skin and located predominantly in the anogenital area. Extragenital lichen sclerosus can be found in up to 15% of cases. The exact etiology of the disease is unknown. Considering the strong association between lichen sclerosus and a variety of autoimmune-related disorders including diabetes mellitus, thyroiditis, morphea, vitiligo, alopecia areata, pernicious anemia and ulcerative colitis, an autoimmune etiology is likely.

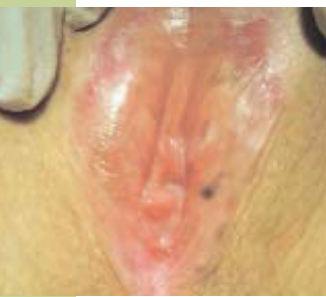There are indications for a genetic link to HLA-DQ7. In addition, there is evidence for familial accumulation. Lichen sclerosus occurs worldwide, although Caucasians seem to be especially affected. The specification of prevalence with 1:1000 has to be regarded cautiously, as epidemiological studies indicate that the disease is insufficiently reported. Patients do not immediately consult a doctor or a clinic and neither gynecologists, dermatologists nor urologists can always attribute the symptoms to the disease. Diagnosis can thus take years.

Previously, lichen sclerosus was called lichen sclerosus et atrophicus. The two medical terms sclerosis and atrophy describe exactly the morphological changes that take place in patients with lichen sclerosus. Sclerosis refers to the process of scarring and cornification, while atrophy refers to strictures. Both phenomena are present in the affected skin regions. However, the two processes may be present to a different extent. This explains why the clinical picture and the symptoms can sometimes vary. The skin and the mucosa of the labia, the clitoris, and the anus of the woman contract due to progressive scarring. This causes the external genitals to progressively shrink. The labia minora fuse, a phimosis of the clitoral hood develops, and

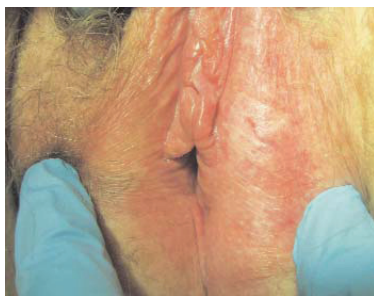the orifice of the urethra is slowly retracted to the stenosing vaginal introitus. The atrophic skin loses its elasticity, appears dry and slight fissures appear. It whitens or, depending on the amount of body fat, may turn yellow.

Clinically, pruritus is the predominant symptom, which can become unbearable during the night and lead to scratch marks, excoriations and thus to secondary lichenification. However, the pruritus may also be less pronounced or completely absent, for example in cases where lichen sclerosus is only beginning or in only small, affected skin areas. Figure 12 shows a limited, periclitoral, porcelain-like change of the clitoris. Histologically, a focal lichen sclerosus was confirmed although the patient was asymptomatic. Pale, porcelain-like papules, that confluence to whitish plaques, are typical findings. They can be characterized either by atrophy or by hyperkeratosis. Due to the chronic course of the disease, atrophic sclerotic (cornified) plaques develop. Introital narrowing almost always causes coital problems. Furthermore, progressive dysuria develops. The affected skin regions cornify and form a layer beneath the skin with pearly, shiny regions of various sizes (Fig. 13). They are often only as small as a pinhead, but may coalesce to form plaques. These skin changes often appear in phases and get more pronounced in the course of the disease. Scratching then leads to additional purpura, fissures, and erosions.

The entire external female genitals may be affected, i.e. the labia minora, labia majora, clitoris, as well as the anal and perianal skin, which creates the classical “figure of eight” shape around the vulva and the anus. Patients presenting with lichen sclerosus most commonly complain of pruritus,



14



15

Figure 14: A 45-year-old women with lichen sclerosus that has persisted for more than ten years with melanosis and loss of the labia
Figure 15: Morbus Paget of the vulva, 60-year-old patient

soreness, dysuria, dyspareunia and defecation pain. If the disease persists for a long time, the labia minora and majora may vanish completely (Fig. 14).

Usually, lichen sclerosus develops in episodes, with sometimes long intermittent phases. Leukoplakia is common and, although lichen sclerosus is not seen as a precancerous disease, a biopsy is always necessary to exclude this.

The major symptom, however, is pruritus vulvae, caused by the skin disorder. It can be so painful that the patient scratches until it bleeds. This, of course, increases the risk for infections, as bacteria and fungi can easily penetrate the damaged skin and cause inflammation, which then makes diagnosis of the underlying cause difficult.

A biopsy is necessary to confirm lichen sclerosus. Histopathologically, there is a firm atrophy of the epidermis with sinuous follicular hyperkeratosis, destruction of the elastic fibers, an edematous soaking of the hyalinized collagen fibers and a strip-like, perivascular lymphocytic infiltrate. Patients who have had long-lasting lichen sclerosus with hyperplastic regions are at an increased risk of squamous cell carcinoma.

The recommended therapy are steroids, either topical or as depot injections in the acute stages of the disease. Here, it is important to note that especially after a long-term course of the disease, the atrophic skin is so sore that ointment preparations will cause burning of the skin. Pure Vaseline with clobetasol has proven successful. It might be reasonable to start with a higher dose, e. g. 0.5% for 14 days and to continue treatment with 0.05% for another month. Due to the dreaded atrophy of the skin by corticosteroids, long-term treatment should be avoided.

Also tacrolimus (as an ointment) – a calcineurin inhibitor – has proven successful in various studies. Topical testosterone should not be applied, as there is no evidence for the effectiveness and it causes severe side effects.

Surgery or the use of CO₂ lasers are problematic, as healing is greatly impaired in the affected areas and the process of atrophy may, in the long run, be accelerated by these interventions.

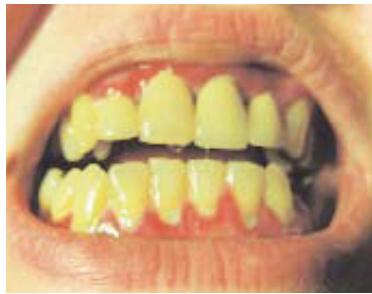Even if lichen sclerosus appears to be the diagnosis, it should always be confirmed by skin biopsy. Figure 15 shows the vulva of a woman, who had a minor pruritus with edematous erythema and a plaque-like, whitish transformation of the labia majora. In a biopsy, however, extramammary Paget's disease was diagnosed, which extended over both labia.

Lichen planus

Lichen planus is a chronic mucocutaneous disease. It is an example for a disease that causes both severe pruritus and painful skin lesions. Lichen planus may affect any age group, but is most common between the third and sixth decade. Various regions of the skin may be affected and appear as red, livid, flattened papules that cause severe itching. Spontaneous healing can be expected after 12 to 24 months.

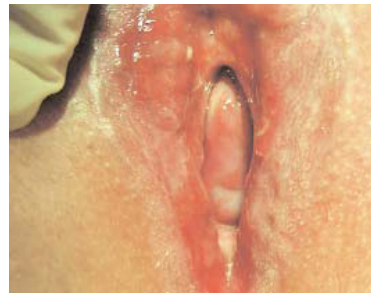When affecting the mucosa (mucosal lichen planus), the oral cavity (Fig. 16) as well as the genitals (Fig. 17), may be affected. Clinically, fernlike and white striae occur. In severe cases, superficial or even deep erythematous lesions of the mucosa may develop, which are very painful. Mucosal lichen planus has a more severe and longer course of disease and especially if the disease is exclusive to the genitals, the affected women will seek advice from their gynecologist. Very often, the areas are overgrown by *Candida spp.* In any case, a biopsy is necessary to confirm diagnosis, especially because squamous cell carcinoma may develop from the atrophy and ulcerous lesions.

The etiology of the disease is unknown. In some cases, it has been associated with the use of certain drugs and it is distributed evenly between men and women. Treatment of lichen planus is the same as for lichen sclerosus, i. e. local corticosteroids or tacrolimus (as an ointment preparation). If the lesions reach within the vagina, there is a danger for adhesions and synechia, which can even cause occlusion of the vagina. Here, surgical expansion as well as intravaginal corticoid foam preparations are indicated.



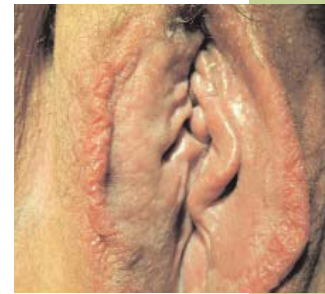16

Figure 16: 42-year-old patient with genital and oral erosive lichen planus; oral manifestation



17

Figure 17: 42-year-old patient with genital and oral erosive lichen planus; genital manifestation



18

Figure 18: Patient with chronic contact dermatitis of the labia majora

Lichen simplex

In contrast to lichen sclerosus, lichen simplex chronicus is unilateral and localized. Intense pruritus leading to unrelenting scratching exacerbates the pruritus and the epithelial changes. In the course of time, the skin thickens and hyperpigmentation develops. Lichen simplex chronicus especially affects adults and can appear on various skin areas. The diagnosis is made histologically by the confirmation of epidermal hyperplasia without any inflammatory reaction. It is regarded as a variant of ectopic eczema as well as a type of neurodermitis. In contrast to other body parts such as breast, neck and head, the genitals are only rarely affected. Treatment includes topical corticosteroids. In cases of extreme pruritus, histamine antagonists can be applied.

Contact dermatitis

In general, the term “contact dermatitis” describes an inflammation of the skin resulting from an exposure of the skin to external allergens. The skin reaction is inflammatory and non-infectious, i.e. an intolerance. Eczema can be caused by various external pollutants. Allergic contact dermatitis, however, is a delayed type hypersensitivity reaction, caused by exposure to an allergen, against which the person has been sensitized previously. Potential allergens can be found in jewelry, skin care products, topical pharmaceuticals, plants and biological agents. In a sensitized person, the eczema usually develops 24 to 72 hours after exposure to the allergen.

Clinically, acute contact dermatitis is characterized by a red rash, swelling, papules, blisters or wheals. The clinical picture is polymorphic, although not all symptoms have to be present. Often, pruritus, burning and soreness are present. Chronic eczema is characterized by lichenification,

desquamation and sometimes rhagades and is monomorphic. Pruritus, burning and soreness are usually as pronounced as in acute eczema. The skin appears dry and scaly (Fig. 18). In the chronic type, the epidermis is widened.

Diagnosis is confirmed by history taking, clinical examination and a patch test. However, the term “eczema” covers a broad range of diseases and other types of eczema such as contact irritant dermatitis, atopic eczema, venous eczema, asteatotic eczema, dyshidrosis and seborrhoeic dermatitis have to be taken into account. Especially in the vulvar region, a so-called cumulative toxic contact dermatitis is possible, which develops after various subliminal skin damages. Symptoms only develop after passing the individual threshold. Cleaning agents, detergents, disinfectants and solvents, remaining detergent additives in the clothes, food, heat, cold, and friction may contribute to cumulative toxic contact dermatitis. Some cases of vulvodinia can be attributed to this field.

In contrast to drug-toxic events, an allergic drug reaction is an IgE-mediated type I hypersensitivity. Accordingly, a previous sensitization is necessary. In a sensitized individual, the intake of a single dose is sufficient to cause a severe incident. Clinically, the allergic reactions ranges from urticarial to anaphylactic reactions and, in most cases, it occurs within the first minutes after taking the drug. However, these reactions only rarely occur exclusively in the genital area.

CME Prakt Fortbild Gynakol Geburtsmed Gynakol
Endokrinol 2009;5(3): 206–218

Keywords

Genital pruritus, genital infection, dystrophy, dermatosis,
genital neoplasia

References

- SMITH YR, HAEFNER HK.** Vulvar lichen sclerosus: pathophysiology and treatment. *Am J Clin Dermatol* 2004; 5(2): 105–25.
- LOTERY HE, GALASK RP.** Erosive lichen planus of the vulva and vagina. *Obstet Gynecol* 2003; 101(5): 1121–5.
- EISEN D.** The vulvovaginal-gingival syndrome of lichen planus. The clinical characteristics of 22 patients. *Arch Dermatol* 1994; 130(11): 1379–82.
- BAMBAO C, SHIER M.** Extramammary Paget's disease of the vulva. *J Obstet Gynaecol Can* 2009; 31(6): 481–2.
- EVANS AT, NEVEN P.** Invasive adenocarcinoma arising in extramammary Paget's disease of the vulva. *Histopathology* 1991; 18(4): 355–60.
- CAPPUCCINI F, TEWARI K, ROGERS LW, DiSAIA PJ.** Extramammary Paget's disease of the vulva: metastases to the bone marrow in the absence of an underlying adenocarcinoma – case report and literature review. *Gynecol Oncol* 1997; 66(1): 146–50.
- NARDELLI A, DEGREEF H, GOOSSENS A.** Contact allergic reactions of the vulva: a 14-year review. *Dermatitis* 2004; 15(3): 131–6.
- SCHÄFER A.** Infektionen in der Gynäkologie. *CME Prakt Fortbild Gynakol Geburtsmed Gynakol Endokrinol* 2/2006: 60–79.
- USMANI N, WILKINSON SM.** Allergic skin disease: investigation of both immediate- and delayed-type hypersensitivity is essential. *Clin Exp Allergy* 2007; 37(10): 1541–6.



Priv.-Doz. Dr. med. Dr. rer. nat. Axel Schäfer

Frauenklinik
Campus Virchow-Klinikum
Charité – Universitätsmedizin Berlin
Augustenburger Platz 1
13353 Berlin

Born 1950 in Berlin, Priv.-Doz. Dr. Schäfer studied biology and medicine in Berlin and graphics in Berlin and Kobe. Since 1992, he is senior physician in Berlin at the Charité/Virchow clinic.

Conflict of interest

The author declares that there is no conflict of interest as defined by the guidelines of the International Committee of Medical Journal Editors (ICMJE; www.icmje.org).

Manuscript information

Submitted on: 25.07.2009

Accepted on: 22.09.2009

Pruritus vulvae

Question 1

A 38-year-old patient with two small children visits you during your consultation-hour. She reports that about two months ago, she noticed a small spot on her vulva that sometimes itches when she rides her bike. You see an eight-millimeter wide, red and slightly elevated area a little below the posterior commissure. What is your first thought?

- Considering the tight sportswear of cyclists and inevitable sweating, the reason is certainly a deep and local fungal infection.
- The proximity to the anal region in a mother with small children lets us draw the conclusion that the patient suffers from a worm infection.
- Due to the hard saddle on a racing bike, the injury is without doubt caused by friction, has been superinfected by vaginal discharge and now causes pruritus due to the healing process.
- As the lesion is inconclusive, a neoplasia has got to be considered, despite the young age of the patient.
- This is a clear case of chronic strain of the perineal region, which expresses itself as irritant dermatitis.

Question 2

What is the main diagnostic approach in the above-described patient (question 1)?

- A fungus culture is the only necessary step.
- Worm detection from the stool or from sellotape is possible; no further diagnostic procedures are necessary.
- You take a smear from the lesion with adequate microbiological differentiation; no further diagnostic procedures are necessary.
- You take a biopsy sample from the lesion.
- In order to advance in this case, it is reasonable to protect the area with fatty creams or healing ointments; no further diagnostic procedures are necessary.

Question 3

A 56-year-old patient visits you and complains about a genital pruritus that has existed for years. She experiences intercourse as extremely painful. She has been treated for fungal infections for years, however, recently without success. You may assume that lichen sclerosus is responsible for the complaints. Which of the following details from the patient does *not* fit this diagnosis?

- The patient says that the pruritus is worse during nighttime than during daytime.
- The patient says that warmth worsens the pruritus.
- The patient says that many ointments that she got during the course of treatment caused burning so that she discontinued taking them.
- The patient says that she has the feeling that her labia minora have become smaller and that the vestibular area of the vagina has tightened.
- The patient says that the symptoms seize if she has no sexual intercourse with her partner for a longer period.

Question 4

In vulvar pruritus, ...

- ... a fungal infection is confirmed by a positive fungal culture,
- ... a bacterial dysbiosis or a bacterial vaginosis are to be expected secondary to the increased vaginal discharge,
- ... a lichen sclerosus should be expected if the fungal culture is negative and there is a so-called resident flora in the bacterial culture,
- ... a psychogenic cause is to be expected if no infection was detected,
- none of the above answers a-d is correct.

Question 5

A 22-year-old patient visits your consultation hour and complains about pruritus and stinging in the region of the mons pubis, but also on the labia majora, which have existed for quite some time. You observe a clitoral piercing and that the vulva of the patient is shaved, typical for this age group. The skin is not red, but you can see that the pubic hair regrows crosswise and that in some areas, tiny papules with pus have developed. What is the most probable cause of the patient's pruritus?

- You assume a local allergic reaction caused by possible Nickel admixtures to the silver of the piercing.
- You assume that the pierce of the ring is the origin for an infection.
- You assume that the regrowing pubic hair in the hair follicles causes pruritus and that this, in turn, causes a pseudofolliculitis barbae.
- You assume microlesions secondary to shaving or admixtures in the shaving foam, which could have caused the symptoms.
- You assume that the attention devoted to the genitals leads to a certain fixation, which would be best explored from a psychosomatic viewpoint.

Question 6

In a patient with genital pruritus, when would you rather assume a lichen simplex chronicus instead of a lichen sclerosus?

- The skin appears tense and has a whitened, porcelain-like appearance.
- Histologically, there is an atrophy of the epidermis with follicular hyperkeratosis and a perivascular lymphocytic infiltrate.
- Epithelial lesions and scratch marks are present.
- There is a pigmentation disorder in the sense of a hyperpigmentation. Histologically, there is hyperplasia of the epidermis without any signs of an inflammatory reaction.
- There are whitened, partly cornified regions.

Question 7

A 38-year-old woman visits you and reports pruritus, burning and dyspareunia. You examine the patient. There is no increased vaginal discharge. In the wet mount, you find a normal mixed flora, no signs for an infection and no increase in the number of leukocytes. The genital area is not or only discretely red. However, you can see single, small fissures, especially on the posterior commissure. The HSV-DNA test and also the HSV IgM serology, however, are negative. All cultures indicate a physiological resident flora. Histologically, no definite diagnosis can be made apart from a slightly inflamed, irritant reaction. What will you do with the patient?

- You refer the patient to a special consultation for fungal infections.
- You resort to alternative therapies because of recommendations from pharmaceutical sales representatives.
- You refer the patient to a dermatologic consultation.
- You refer the patient to an internistic-infectious consultation, in order to clarify whether a systemic infection might have caused the symptoms.
- You point out to the patient that also psychosexual disorders may cause such symptoms and advise her to seek attendance.

Question 8

A 47-year-old patient complains about genital pruritus. You see livid, flat papules and flat, plaque-like lesions of the skin at the vaginal orifice and the posterior commissure. You assume lichen planus. Which of the following statements is *correct*?

- Looking into the oral cavity is not necessary. As a gynecologist, you cannot draw any information from examining the oral cavity.
- As the clinical picture indicates lichen planus, a biopsy is not necessary.
- The mucosal type of lichen planus is restricted to under a year.
- In lichen planus, a superinfection of the erosive lesions can be excluded.
- The erosive lesions may be superinfected in lichen planus. *Candida spp.* are often detected in a culture, however, they do not predominate in the pathogenesis of the symptoms.

Question 9

A small girl, eight years of age, visits your practice. The mother is worried, because she observed that her daughter was constantly scratching her genitals. You see a whitened appearance of the skin, which reaches until the anus. What diagnosis do you assume as a reason for those complaints and changes?

- a. You assume lichen sclerosus, which will usually seize with the onset of puberty.
- b. The vaginal discharge is not increased, but as you cannot see any lactobacilli but almost exclusively anaerobic bacteria, you assume a bacterial vaginosis.
- c. You assume that a mechanical irritation by scratching has caused the skin changes.
- d. You assume that a chronic contact dermatitis with lichenification is present, and refer the girl to a dermatologist to perform a patch test.
- e. You assume an infection with mycoplasma or chlamydia, which may have an atypical course at that age with involvement of the vaginal mucosal epithelial layer.

Question 10

Why is the long-term topical use of corticosteroids in vulvar atrophy potentially dangerous?

- a. Local immunosuppression predisposes for other opportunistic pathogens.
- b. Even with a local application, only small amounts are resorbed, however, these may worsen the diabetes.
- c. Also a longer topical use can cause side effects such as weight gain.
- d. Long-term use of corticosteroid preparations can lead to atrophy of the skin.
- e. Even a topical use can cause acute glaucoma, especially in elderly patients.