

# Sexual function and fertility preservation in cancer patients

Juliane Farthmann, Annette Hasenburg  
Universitäts-Frauenklinik Freiburg

Reviewers: Nicole Gehrman, Berlin  
and Alexandra Coumbos, Hamburg

## Summary

The potential impact of cancer therapies like surgery, chemotherapy or radiation therapy on sexual function and fertility needs to be discussed openly with each patient. In younger patients, cancer therapy may result in ceasing ovarian function and fertility loss, while postmenopausal women will suffer from androgen deprivation. Physicians have to acknowledge the fact that sexuality is an important component of quality of life. It is thus necessary that the patient be informed about the potential treatment effects on sexuality, including therapeutic or preventive options. From an oncological point of view, local or even systemic administration of estrogens is considered safe for the majority of gynecologic oncology patients. Apart from local therapies, physical therapy and exercise are supportive options. The side effects, which cancer treatment might have on fertility depend on the patient's age, the stage of the disease, the type of treatment, and on the sensitivity of the ovarian tissue. Information on different fertility preservation options and contact data of fertility centers can be obtained from the network FertiPROTEKT ([www.fertiprotekt.de](http://www.fertiprotekt.de)).

## Introduction

After the confrontation with the diagnosis of cancer, the patient's primary concern is to be cured. However, the patient gradually becomes aware of the long-term side effects of the necessary therapeutic interventions. Important elements of quality of life may be affected considerably such as the patient's body image and sexual functions.

## Consequences of cancer therapy

Cancer treatment, whether exclusively operative or combined with chemotherapy or radiation therapy, very often results in gonadal insufficiency. Premenopausal patients are likely to suffer from premature onset of menopause, while postmenopausal patients may suffer from libido loss. The stromal cells and the hilar interstitial cells in the ovaries are essential for the synthesis of androgens (testosterone and androstendione), which, among other factors,

preserve a woman's libido after menopause. Thus, the damaging effects of cancer treatment on the gonads affect all age groups, a fact which has to be considered when making therapeutic decisions.

## An exceptional challenge: Fertility preservation in oncology

An exceptional challenge for the caring physician is the premenopausal patient. Either they are planning to have children or have not given family planning much thought, especially if they are single at the time of diagnosis. It is the clinician's responsibility to communicate not only the cancer-associated issues but also the consequences the therapeutic interventions may have on the patient's fertility. A multidisciplinary approach is necessary and the patient should be advised to visit a fertility center prior to therapy initiation.

## Demands on the caring physician

Although sexuality is a taboo issue, the potential long-term consequences of oncologic therapy on sexual function and quality of life in general have to be considered and discussed with the patient.

Although sexual dysfunction has special implications in gynecologic cancers, anti-cancer therapy for other malignancies is equally likely to cause those side effects. Medical innovations have improved the survival rates for patients with malignant diseases making it necessary to take care of the patient's quality of life.

## Possible approaches

Until now, we do not have many options to prevent cancer therapy from causing premature menopause and sexual dysfunction. Thus, prior to therapy, it is important to inform the patients about all possible side effects. Many patients will only comprehend the side effects of their therapy retrospectively.

The aim of this article is to sensitize the reader to the subject of sexual function in cancer patients and provide management strategies. The general and disease-specific changes of sexual function caused by oncologic therapies

are outlined. In current literature, breast cancer-associated sexual function or body image are discussed extensively, other entities are less represented. In the following sections, we focus on gynecologic malignancies.

### Changes in body image after surgery

Due to the continuous innovations in gynecologic oncology, treatment today is often multimodal, which makes it necessary to differentiate between the side effects of the various therapeutic interventions. Patients very often face therapeutic consequences that may be visible to others such as hair loss, scars, the missing breast or a preternatural anus and a neo-bladder (Fig. 1). These are stigmata that can greatly alter the patient's body image and may reduce self-esteem. The patient may feel less attractive, and even quit leisure time activities because of being ashamed of her appearance. In contrast, other elements of cancer treatment such as chemotherapy, hormone therapy or antibody therapy may have a functional impact on body functions. Side effects such as the fatigue syndrome or coexisting depressive disorders are common and may additionally affect the sexual life of a patient (Reich et al. 2008).

Premenopausal patients may experience premature menopause including symptoms such as mood swings, hot flashes, libido loss and insufficient lubrication.


Yi and Syrjala showed that high-dose chemotherapy and stem-cell transplantation often cause sexual dysfunction by damaging the gonads, which, in turn, causes hormonal changes. More women than men are affected and only early diagnosis and treatment can prevent chronic manifestation (Yi and Syrjala 2009).

### Breast cancer

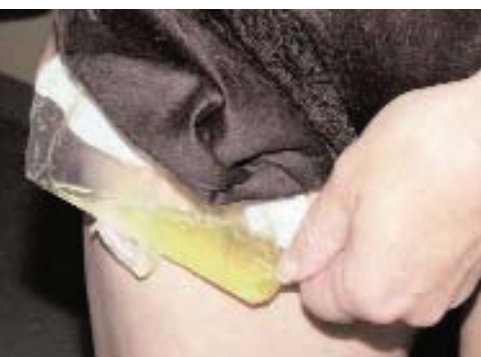No other body part represents femininity as much as the breast does. Accordingly, mastectomy is a dramatic event for the patient, as her physical integrity may be disrupted (Helms et al. 2008). The various consequences of breast-conserving therapy versus mastectomy have been described. Mastectomy and breast reconstruction procedures affect the patient's sexual function far more than breast-conserving therapy. However, the differences between the two groups concerning selected aspects of sexual life, such as desire, orgasm, and satisfaction, were only small. One year after having received the diagnosis, the women's quality of life was rather determined by adjuvant therapy than by the operation (Rowland et al. 2000).

Fobair et al. showed that severe sexual dysfunction in patients with breast cancer was specifically associated with vaginal dryness and psychological problems. The majority of the women who participated in the study were married and their partners lacked understanding. The authors therefore recommend discussing the possible effects of oncological treatment on the patient's relationship with the couple and offer support for the partner, if necessary (Fobair et al. 2006).

In approximately 60% of cases, breast cancer can be treated with breast-conserving therapy with a satisfactory cosmetic outcome and a sufficient oncological safety ("Interdisziplinäre S3-Leitlinie für die Diagnostik, Therapie und Nachsorge des Mammakarzinoms, 1. Aktualisierung 2008"). The patient's "physical integrity" can thus be preserved in the majority of cases. If a mastectomy has to be



a



b

Figure 1: Patient after anterior exenteration with satisfactory sexual function. In order to conceal the urostomy bag, she sewed herself a bag with the cloth/material of a second slip (provided by Prof. Dr. A. Hasenburg, Freiburg)

performed for medical reasons, the patient should be informed about the possibilities of breast reconstruction with autologous tissue or implants.

### Ovarian cancer

Therapy of ovarian cancer according to the AGO (Arbeitsgemeinschaft Gynäkologische Onkologie) guidelines includes hysterectomy, omentectomy, bilateral adnectomy, pelvic and para-aortic lymphadenectomy as well as additional interventions in order to achieve a complete resection of the tumor. Only for early-stage cancers (Ia G1) and in patients with the desire to have a child, the possibility of fertility-preserving surgery should be discussed.

In premenopausal women, adnectomy results in the sudden onset of menopausal symptoms. Thus, hormone replacement therapy (HRT) options should be explored preoperatively.

### Ability to reach orgasm secondary to pelvic and para-aortic lymphadenectomy

After therapy of ovarian cancer, 75% of patients have difficulties to reach orgasm (Taylor et al. 2004). Until now, it has not been clarified whether this results from the severity of the disease and the chemotherapy or from the pelvic and para-aortic lymphadenectomy itself. The latter could cause damage to the autonomic nerves, comparable to prostate cancer surgery in men (Madeb et al. 2007).

A current study from the “AGO-Ovar” (a working group on gynecological oncology) is supposed to resolve this question: the LION study (Lymph nodes In Ovarian Neoplasm), a prospective randomized study, examines whether women with advanced ovarian cancer in whom complete intra-abdominal resection could be achieved, will profit from systemic pelvic and para-aortic lymphadenectomy. A sub-study, LION-PAW (Lymph nodes In Ovarian Neoplasm - Pleasure Ability of Women), has the aim to clarify to which extent a radical lymphadenectomy affects the women's sexual function.

### Uterine cancer (cervical or endometrial cancer)

In a radical hysterectomy after Wertheim-Meigs technique, the standard therapy for cervical cancer, the ovaries can be preserved in most cases of squamous cell carcinoma, preventing the sudden onset of menopause. Also in early stages of endometrial carcinoma, adnectomy can be avoided in premenopausal patients without causing increased treatment failure (Wright et al. 2009).

Nevertheless, radical hysterectomy may have impairing side effects on sexual function. Serati et al. showed that women after this operation had a significantly reduced sexual function compared to a healthy control group. In a questionnaire, the factors sexual desire, arousal, lubrication

of the vagina, ability to reach orgasm or orgasmic frequency, satisfaction, and pain were assessed. The differences were confirmed in all points. No significant differences could be found between patients who had undergone a laparoscopic procedure and those who had undergone open abdominal surgery (Serati et al. 2009).

After adjuvant radiotherapy or primary radio-chemotherapy, women often suffer from vaginal strictures and adhesions as well as from a reduced lubrication of the vagina (Fraunholz et al. 1998). This may result in severe impairments of sexual function, the severity of which correlates with FIGO staging (Saewong and Choobun 2005). Ditto et al. showed that the combination of radical hysterectomy and adjuvant radiation therapy, independent of the method of the performed radical hysterectomy, had an additional negative effect on sexual function (Ditto et al. 2009).

### Vulvar/vaginal cancer

In vulvar or vaginal cancer, the disease is usually locally confined. However, in some cases, an extensive resection may be necessary, which can alter the external genital organs of the woman. Similar to patients with breast cancer in whom radical operations in the Rotter-Halsted technique were performed, in former times, patients with vulvar carcinoma had to undergo radical vulvectomy. This included en-bloc resection of the labia majora and labia minora, the clitoris and the inguino-femoral lymph nodes.

Today it is accepted that an organ-preserving “wide local excision” is, in the majority of cases, sufficient, while ensuring the same oncologic safety (de Hullu and van der Zee 2006).

The surgical approach should be tailored to preserve the patient's ability for cohabitation and to reach orgasm. This is especially challenging if the malignancy is located in the vicinity of the clitoris. In some cases of pre-invasive cancer, the exclusive removal of clitoral skin is possible and the defect can be covered with reconstructive measures. (Fig. 2) (Terlou et al. 2008). As an extensive vulvectomy may cause severe strictures of the introitus, reconstructive surgery with placement of flaps should be performed in order to limit the risk for such consequences (Fig. 3a-c).

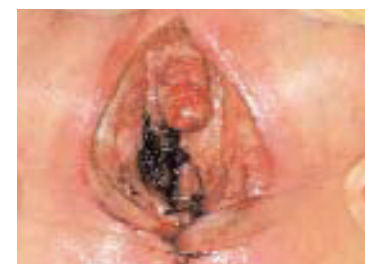
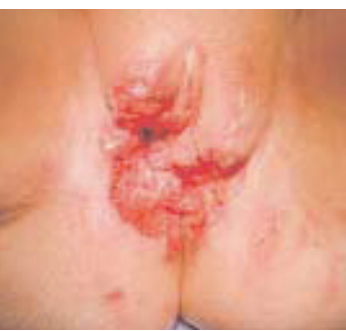
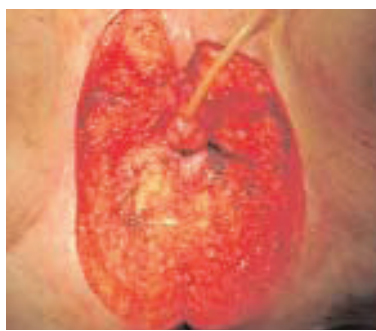Figure 2: De-epithelialization of the clitoris in VIN III (vulvar intraepithelial neoplasia)



a



b

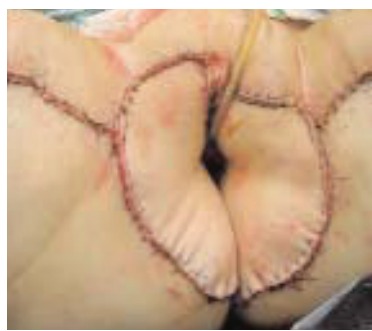

Figure 3: Preoperative situs in vulvar cancer in stage III (a); intraoperative situs in posterior exenteration and plastic covering and preservation of the vagina (b); postoperative situs (c) (provided by Prof. Dr. A. Hasenburg, Freiburg)

Likes et al. observed that the patient's age as well as the degree of surgical radicality correlated with a reduced sexual function and quality of life (Likes et al. 2007). Therefore, the consequences of the surgical intervention have to be discussed extensively with the patient prior to surgery. Even for elderly patients, maintaining sexual function may be of great importance (Brähler and Unger 1994).

#### Other malignancies

In women who are treated for non-gynecologic malignancies, the consequences of therapy on fertility and sexual function are often not recognized as such and not discussed with the patient prior to therapy initiation. In hematologic diseases, the chances of cure are often very good with intensive therapy. At the beginning of therapy, cure is the main concern of the patients, daily needs such as satisfactory sexual function as an aspect of quality of life only emerge once the patient has returned to her ordinary daily life. Thus, patients often realize the treatment consequences very late, for example when experiencing premature menopause.

#### Palliation

The progress made in the therapy of oncological diseases has increased the life expectancy of patients (Deutsches Krebsforschungszentrum: [www.krebsinformationsdienst.de](http://www.krebsinformationsdienst.de)). Even though patients cannot always be cured, they often live in a palliative situation for months and years. The idea of palliation is to maintain quality of life for as long as possible. Preservation of sexual function can be seen as one aspect. Thus, also in patients that cannot be cured, this topic has to be discussed and it should be attempted to preserve or improve sexual function and the patient's body image.

#### Psychological problems

Very often, the somatic and psychological problems of sexual dysfunction are difficult to separate and are interdependent. Both aspects thus have to be considered by the physician. If the patient manages to accept the disease and the associated physical changes, it is easier for her to return to satisfactory sexual function. The situation is especially challenging in young women who are single and have to confront their new partner with their disease. Often, a partner can only stand passively and helplessly at the patient's side. Due to false considerations, the couple might not talk about this issue, thus, a vicious circle may develop (Fig. 4), out of which the couple may have difficulties to escape. On the other hand, the disease can be seen as a chance for intensifying a relationship (Rowland et al. 2009).

#### Therapeutic options

First and foremost, it is important to sensitize physicians working in oncology. The patient has to be informed about the long-term consequences of the scheduled therapy as well as the effects on sexual function and fertility.

Boehmer et al. showed that homosexual women often have fewer problems with their sexual function after suffering from cancer compared to heterosexual women, as they experience very good mental support from their partners. They had fewer lubrication disorders or problems reaching orgasm and had a better body image than heterosexual women. On the other hand, it was more difficult for these patients to receive professional help and information, which might be due to a sexual taboo. The authors, however, express that further studies are required to clarify this issue (Boehmer et al. 2009).

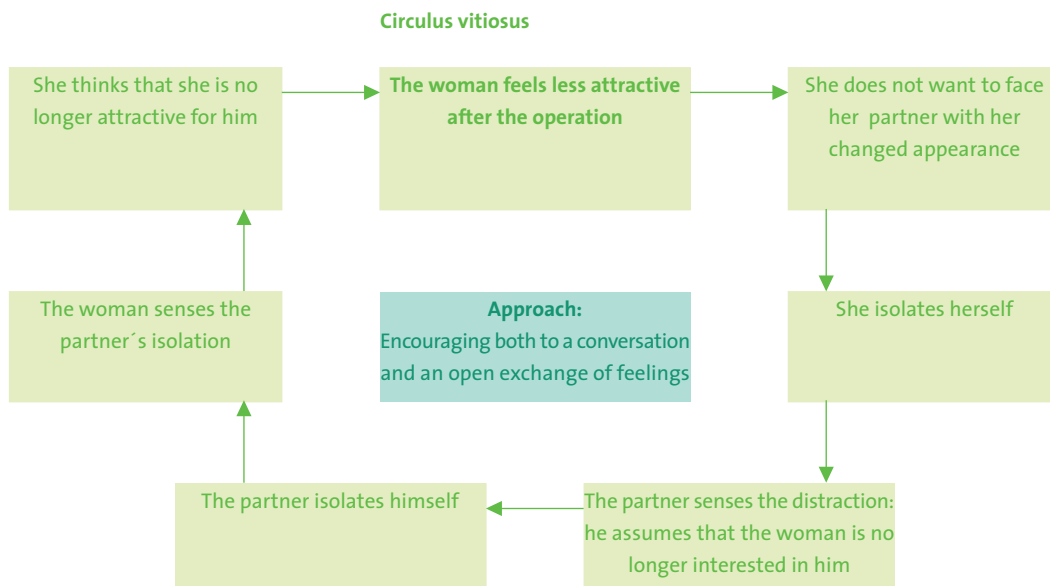


Figure 4: Vicious circle: effects of lack of communication of a couple in which the woman suffers from cancer

### Vaginal dilators

Patients who have undergone radiation therapy of the pelvis or brachy-therapy should be made aware of the available treatment options for vaginal strictures or adhesions, which preserve the patient's ability for cohabitation. These include vaginal dilators or bepanthen tampons, which can be combined with estrogen-containing lotions or lubricants. Treatment can be initiated four to six weeks after radiation therapy (Interdisziplinäre Leitlinie der Deutschen Krebsgesellschaft e.V. und der Deutschen Gesellschaft für Gynäkologie und Geburtshilfe: Diagnostik und Therapie des Zervixkarzinoms, Stand 2008). It is important to use the vaginal dilators regularly (e.g. Dilator Set®), even if the patient is not in a relationship, as dilation of the vagina becomes increasingly difficult with time. Accompanying pelvic floor muscle training results in the gain over muscle identification, control and strength. Possible fears of the patient such as manipulating their own genitals or resuming of sexual intercourse should be actively discussed.

### Local estrogen therapy

Local estrogen therapy of the vagina improves lubrication of the vagina and facilitates cohabitation. By applying local estrogens, however, the systemic estrogen concentration may reach levels that are usually achieved with oral estrogens (Sitruk-Ware et al. 1990). Thus, topic treatment should be critically assessed, depending on the present malignancy. In patients with hormone receptor-positive breast cancer, estrogen exposure is obsolete. In hormone-receptor negative cancer, it is exclusively recommended to patients with pronounced suffering (Leitlinie Mammakarzinom der AGO 2009).

Similarly, in some cases of endometrial cancer, patients receive local estrogen treatment if suffering severely. Risk-benefit assessment is essential and the patient has to be thoroughly informed (Interdisziplinäre Leitlinie der Deutschen Krebsgesellschaft e.V. und der Deutschen Gesellschaft für Gynäkologie und Geburtshilfe 2008).

In ovarian cancer, local estrogen therapy is not contraindicated (Interdisziplinäre Leitlinie der Deutschen Krebsgesellschaft e.V. und der Deutschen Gesellschaft für Gynäkologie und Geburtshilfe: Diagnostik und Therapie maligner Ovarialtumoren, Stand 2007). As an alternative, estradiol can be substituted with a vaginal ring (Estring®). The systemic effects are reduced while local estrogen effects are sufficient (Henriksson et al. 1996). Serum levels are higher with estrogen patches than with the vaginal ring (Gupta et al. 2008).

If estrogen exposure is contraindicated, a skin care cream or inert lubricants may counteract vaginal dryness.

### Hormone replacement therapy (HRT)

Natural menopause is caused by the slow cessation of ovarian function causing a variety of systemic symptoms, which can be treated with hormone replacement therapy (HRT). However, both physicians and patients are increasingly criticizing the use of HRT in healthy women, which is supported by extensive clinical studies such as the "Women's Health Initiative" and the "Nurses' Health Study" (Writing Group for the Women's Health Initiative Investigators 2002).

Acute onset of menopause, however, can occur a few days after adnectomy in premenopausal patients. The consequences are postoperative depressive episodes due to sudden hormone deprivation and long-term consequences such as osteoporosis or sexual dysfunction. The possibilities of hormone replacement therapy should therefore be discussed with the patient already prior to surgery.

If quality of life is reduced due to estrogen deprivation secondary to ovarian cancer, hormone therapy with sexual steroids can be initiated after a careful risk-benefit assessment. In patients with an endometrioid histology, low-dose-estrogens should be combined with a progesterone therapy (Interdisziplinäre Leitlinie der Deutschen Krebsgesellschaft e.V. und der Deutschen Gesellschaft für Gynäkologie und Geburtshilfe: Diagnostik und Therapie maligner Ovarialtumoren, Stand 05/2007).

In a study of postmenopausal patients with ovarian cancer Michaelson-Cohen et al. showed that HRT treatment is not associated with an increased risk of recurrence (Michaelson-Cohen et al. 2009). Already in 2006, Mascarenhas et al. had observed an improved overall survival rate with HRT for patients with ovarian cancer or borderline ovarian tumors (n = 799, multivariate hazard ratio = 0.57; 95%-CI: 0.42-0.78, Mascarenhas et al. 2006).

If, secondary to endometrial cancer, a patient suffers from severe postmenopausal symptoms, a medium dose of progesterone (e.g. 20 mg medroxyprogesterone acetate) can keep the symptoms under control without an increased risk of recurrence (Interdisziplinäre Leitlinie der deutschen Krebsgesellschaft e.V. und der Deutschen Gesellschaft für Gynäkologie und Geburtshilfe: Diagnostik und Therapie des Endometriumkarzinoms; Stand 2008).

In premenopausal patients with endometrial or ovarian cancer, the loss of ovarian function is inevitable and thus an indication for HRT. In general, estrogens have no contraindications. However, after radiation therapy of cervical cancer, estrogens should always be combined with progesterones due to the risk of endometrial cancer ("Manual Zervixkarzinom", Tumorzentrum München).

Hormone therapy after breast cancer has strict indications. The patient's quality of life has to be severely impaired and an individual risk-benefit assessment is required. In hormone receptor-positive breast cancer patients, hormone therapy is currently contraindicated (S2-Leitlinie Hormontherapie 2008, Pritchard et al. 2002).

Table 1 summarizes the local and systemic estrogen therapy options.

Table 1: Options for local or systemic hormone therapy after gynecologic cancer\*

	Local estrogens	Hormone replacement therapy
<b>Breast cancer (considerable suffering)</b>	HR-pos.: no HR-neg.: possible	no no
<b>Ovarian cancer</b>	yes	yes
<b>Cervical cancer</b>	squamous cell carcinoma: yes adenocarcinoma: no	squamous cell carcinoma: yes adenocarcinoma: no
<b>Uterine corpus cancer</b>	yes	yes (progesterone)
<b>Vulvar cancer</b>	yes	yes
<b>Vaginal cancer</b>	HR-pos.: no HR-neg.: yes	HR pos.: no HR neg.: yes
<b>Non-gynecologic malignancies</b>	yes	yes

\*Sources: Guidelines of the working group gynecologic oncology (Arbeitsgemeinschaft Gynäkologische Onkologie, AGO) and interdisciplinary guidelines of the German Cancer Society e.V. (Deutsche Krebsgesellschaft e.V. (DKG) and the German association for Gynecology and Obstetrics (Deutsche Gesellschaft für Gynäkologie und Geburtshilfe, DGGG)

### Testosterone

Only a few years ago, almost all postmenopausal patients that underwent hysterectomy received prophylactic oophorectomy, as it was generally assumed that postmenopausal ovaries ceased to produce hormones. However, since then, several studies have proven that the ovaries of postmenopausal women continue to produce androgens, which are, among other factors, important for maintaining libido (Fogle et al. 2007). For libido loss after inevitable adnectomy, testosterone substitution via a transdermal system is recommended (Buster et al. 2005; Davis et al. 2008). Testosterone patches (e.g. Intrinsic®) have not been tested in patients with gynecological malignancies and an off-label use in patients requires thorough information of the patient; specific documentation is recommended.

### Fertility preservation

Cancer affecting young women prior to having children represents a struggle for both the patient as well as the

caring physician. Cancer treatment does not only impair sexual function and body image, but also loss of reproductive function with premature menopause, i.e. the onset of menopause before the age of 40 (Beckmann et al. 2006).

The treatment effects on ovarian function depend on the patient's age, the stage of the disease, the dose and type of drug, the localization and radiation dosage as well as extensions of the radiation field and on the individual susceptibility of the ovaries. In younger patients, the ovarian reserve is greater, thus, depending on the chemotherapeutic regimen, reproductive function can be preserved and premature ovarian failure can be prevented.

Oktay and Oktem showed that prophylactic administration of GnRH analogues in children showed no benefits regarding fertility preservation. In prepubertal girls, cryopreservation of ovarian tissue is an option, while in postpubertal girls, oocyte cryopreservation is recommended (Oktay and Oktem 2009).

Prior to cancer therapy, the premenopausal patient who is planning to have a child has to be informed about the treatment side effects on her reproductive function and the available options of fertility preservation. She should be counseled at a reproductive medicine center prior to initiating therapy.

Depending on the type and urgency of the scheduled therapy, various options are available (Hanjalic-Beck et al. 2009).

### **In vitro fertilization (IVF) and intracytoplasmic sperm injection (ICSI)**

IVF and ICSI can be performed prior to chemotherapy if the scheduled therapy can be postponed by two to four weeks. Oocytes are fertilized with the partner's sperm and cryopreserved.

### **In vitro follicle maturation**

If ovarian stimulation is contraindicated or if chemotherapy can only be delayed by one to three weeks, in vitro follicle maturation represents an alternative. Immature oocytes are harvested without the exposure to exogenous hormone stimulation and grown in vitro for one to two days. Subsequently, the mature oocytes can be cryopreserved directly or fertilized and then frozen. However, thus far, this elaborate and expensive technique has only rarely been used.

### **Cryopreservation of oocytes and ovarian tissue**

For patients that do not have a partner at the time of diagnosis, cryopreservation of unfertilized oocytes is another option. Here, oocytes and ovarian tissue are obtained by hormone stimulation and cryopreservation. The oocytes are then fertilized in vitro. However, the unfertilized oocytes are highly vulnerable. Cryopreserva-

tion of ovarian tissue is possible in very young women, or if cancer therapy has to be initiated immediately.

### **Transposition of the ovaries**

Before a scheduled pelvic radiation therapy with the ovaries lying in the radiation field, laparoscopic ovariopexy should be performed. Even at a low radiation dosage, the ovaries may be damaged.

### **GnRH analogues**

The administration of GnRH analogues causes suppression of ovarian function, thus, the ovaries are less susceptible to chemotherapy. These agents are rapidly available and provide an acceptable tolerance.

A sensitive predictor for assessing the ovarian reserve before or after cancer therapy is the serum anti-müllerian hormone (AMH) level. The hormone is produced by the granulosa cells of the primary, secondary and pre-antral follicles (van Rooij et al. 2005).

If a patient develops the desire to have a child years after cytotoxic therapy and was not consulted and treated adequately at the time, even assisted reproduction may not be able to help her.

Also in malignant diseases that require a fast therapeutic intervention within only a few days such as acute leukemia, there is enough time for consultation and follicle harvesting for cryopreservation (Oktay et al. 2004).

In order to improve treatment for the affected patients and the training of all colleagues working in oncology, the network FertiPROTEKT was founded several years ago ([www.fertiprotekt.de](http://www.fertiprotekt.de)). It is an association of centers for reproductive medicine in Germany. The network consults and informs doctors as well as patients about fertility preservation.

### **Psychotherapy**

Rowland et al. showed that a 6-week psychological intervention improved the overall sexual satisfaction in patients suffering from breast cancer. However, there were no differences concerning specific aspects such as dyspareunia or variations in their sexual life. Referring to the authors, those patients, who had demonstrated the greatest dissatisfaction before the intervention, had the greatest benefit (Rowland et al. 2009). Also Joske et al. observed a positive effect of psychotherapeutic intervention on the quality of a relationship during and after cancer (Joske et al. 2006).

A coexisting depression should be thoroughly assessed. Specific pharmacotherapy might be necessary and the depression should not be treated with hormones. Although most antidepressants can cause transient libido loss, a

temporary treatment with 10 mg to 20 mg (max. 40 mg) citalopram for three to six months should be considered if the depressive disorder prevails. If the overall well-being improves, also the sexual life and the relationship might benefit (Hasenburg et al. 2008).

### Conclusion

An impaired sexual function after treatment of gynecologic malignancies with surgery, radiation therapy and/or chemotherapy significantly limits quality of life.

This may have individual sequelae. While for younger patients infertility may be the major concern, postmenopausal women might consider the loss of the remaining androgen function of the ovaries as most striking.

Furthermore, the consequences of cancer therapies on fertility depend largely on the patient's age, the stage of disease, the dosage and combination of the chemotherapeutic agents, the radiation dosage, the extent of the radiation field and the susceptibility of the ovarian tissue. For instance, the significance of a radical pelvic and para-aortic lymphadenectomy for sexual function remains unclear.

Physicians have an exemplary function when discussing therapy-induced changes in sexual function and should regard sexuality as an essential element of quality of life. Therefore, the possible treatment side effects and the

quality of life after cancer have to be discussed with the patient prior to therapy initiation.

From an oncological point of view, local or systemic estrogen therapy subsequent to treatment of squamous cell carcinoma of the cervix or ovarian cancer is considered an adequate treatment of postmenopausal symptoms. Apart from local symptomatic therapy (e.g. lubricant gel), physical interventions and physical activity should be implemented as supportive measurements.

Information on fertility-preserving interventions (IVF/ICSI, IVM, cryopreservation of oocytes or ovarian tissue, ovary transposition, GnRH analogues) as well as addresses of qualified centers for reproductive medicine are offered by the network FertiPROTEKT ([www.fertiprotekt.de](http://www.fertiprotekt.de)).

CME Prakt Fortbild Gynakol Geburtsmed Gynakol Endokri-  
nol 2009; 5(3): 220-230

### Keywords

Sexual function, fertility preservation, cancer, estrogens



## References

- BECKMANN MW, BINDER H, DITTRICH R, FRIESE K, GERBER B, GITSCH G, JONAT W, KAUFMANN M, KIECHLE M, KREIENBERG R, DIEDRICH K, WALLWIENER D, WILHELM M, WÜRFEL W, ORTMANN O.** Konzeptpapier zur Ovarprotektion. Geburtshilfe Frauenheilkd 2006; 66: 241–251.
- BERAL V; MILLION WOMEN STUDY COLLABORATORS.** Breast cancer and hormone-replacement therapy in the Million Women Study. *Lancet* 2003; 362(9382): 419–27. Erratum in: *Lancet* 2003; 362(9390): 1160.
- BUSTER JE, KINGSBERG SA, AGUIRRE O, BROWN C, BREAUX JG, BUCH A, RODENBERG CA, WEKSELMAN K, CASSON P.** Testosterone patch for low sexual desire in surgically menopausal women: a randomized trial. *Obstet Gynecol* 2005; 105: 944–52.
- BOEHMER U, POTTER J, BOWEN DJ.** Sexual functioning after cancer in sexual minority women. *Cancer J* 2009; 15(1): 65–9.
- BRÄHLER E, UNGER U.** Sexual activity in advanced age in the context of gender, family status and personality aspects – results of a representative survey. *Z Gerontol* 1994; 27(2): 110–5.
- DAVIS SR, MOREAU M, KROLL R, BOUCHARD C, PANAY N, GASS M, BRAUNSTEIN GD, HIRSCHBERG AL, RODENBERG C, PACK S, KOCH H, MOUFAREGE A, STUDD J; APHRODITE STUDY TEAM.** Testosterone for low libido in postmenopausal women not taking estrogen. *N Engl J Med* 2008; 359(19): 2005–17.
- DE HULLU JA, VAN DER ZEE AG.** Surgery and radiotherapy in vulvar cancer. *Crit Rev Oncol Hematol* 2006; 60(1): 38–58. Epub 2006 Jul 10. Review.
- DITTO A, MARTINELLI F, BORREANI C, KUSAMURA S, HANOZET F, BRUNELLI C, ROSSI G, SOLIMA E, FONTANELLI R, ZANABONI F, GRIJUELA B, RASPAGLIESI F.** Quality of life and sexual, bladder, and intestinal dysfunctions after class III nerve-sparing and class II radical hysterectomies: a questionnaire-based study. *Int J Gynecol Cancer* 2009; 19(5): 953–7.
- FOBAIR P, STEWART SL, CHANG S, D'ONOFRIO C, BANKS PJ, BLOOM JR.** Body image and sexual problems in young women with breast cancer. *Psychooncology* 2006; 15(7): 579–94.
- FOGLE RH, STANCZYK FZ, ZHANG X, PAULSON RJ.** Ovarian androgen production in postmenopausal women. *J Clin Endocrinol Metab* 2007; 92(8): 3040–3. Epub 2007 May 22.
- FRAUNHOLZ IB, SCHOPOHL B, BÖTTCHER HD.** Management of radiation injuries of vulva and vagina. *Strahlenther Onkol* 1998; 174(Suppl 3): 90–2.
- GUPTA P, OZEL B, STANCZYK FZ, FELIX JC, MISHILL DR JR.** The effect of transdermal and vaginal estrogen therapy on markers of postmenopausal estrogen status. *Menopause* 2008; 15(1): 94–7.
- HANJALIC-BECK A, LEIBER C, HASENBURG A.** Fertilität und Sexualität. In: Feyer P, Ortner P (Hrsg). *Supportivtherapie in der Onkologie*. München: Urban & Vogel 2009; 110–124. In Press.
- HASENBURG A, GABRIEL B, EINIG E-M.** Sexualität nach Therapie eines Ovarialkarzinoms. *Geburtsh Frauenheilk* 2008; 68: 994–7.
- HELMS RL, O'HEA EL, CORSO M.** Body image issues in women with breast cancer. *Psychol Health Med* 2008; 13(3): 313–25.
- HENRIKSSON L, STJERNQUIST M, BOQUIST L, CEDERGREN I, SELINUS I.** A one-year multi-center study of efficacy and safety of a continuous, low-dose estradiol-releasing vaginal ring (Estring) in postmenopausal women with symptoms and signs of urogenital aging. *Am J Obstet Gynecol* 1996; 174: 85–92.
- HILLEMANN P, HÖSS C, KÜRZL R.** *Manual Zervixkarzinom*. 3. Auflage München: Tumorzentrum München 2004.
- INTERDISZIPLINÄRE LEITLINIE DER DEUTSCHEN KREBSGESELLSCHAFT UND DER DEUTSCHEN GESELLSCHAFT FÜR GYNÄKOLOGIE UND GEBURTSHILFE.** Diagnostik und Therapie des Endometriumkarzinoms. Stand 01/2008.
- INTERDISZIPLINÄRE LEITLINIE DER DEUTSCHEN KREBSGESELLSCHAFT E.V. UND DER DEUTSCHEN GESELLSCHAFT FÜR GYNÄKOLOGIE UND GEBURTSHILFE.** Diagnostik und Therapie maligner Ovarialtumoren. Stand 05/2007.
- INTERDISZIPLINÄRE LEITLINIE DER DEUTSCHEN KREBSGESELLSCHAFT E.V. UND DER DEUTSCHEN GESELLSCHAFT FÜR GYNÄKOLOGIE UND GEBURTSHILFE.** Diagnostik und Therapie des Zervixkarzinoms. Stand 01/2008.
- INTERDISZIPLINÄRE S3-LEITLINIE DER DEUTSCHEN KREBSGESELLSCHAFT E.V. UND DER DEUTSCHEN GESELLSCHAFT FÜR GYNÄKOLOGIE UND GEBURTSHILFE.** Diagnostik, Therapie und Nachsorge des Mammakarzinoms. 1. Aktualisierung 2008.
- JOSKE DJ, RAO A, KRISTJANSON L.** Critical review of complementary therapies in haemato-oncology. *Intern Med J* 2006; 36(9): 579–86. Review.
- LIKES WM, STEGBAUER C, TILLMANN T, PRUETT J.** Correlates of sexual function following vulvar excision. *Gynecol Oncol* 2007; 105(3): 600–3. Epub 2007 Feb 15.
- MADEB R, GOLIJANIN D, KNOPF J, VICENTE I, ERTURK E, PATEL HR, JOSEPH JV.** Patient-reported validated functional outcome after extraperitoneal robotic-assisted nerve-sparing radical prostatectomy. *JSL* 2007; 11(4): 443–8. Review.
- MASCARENHAS C, LAMBE M, BELLOCCO R, BERGFELDT K, RIMAN T, PERSSON I, WEIDERPASS E.** Use of hormone replacement therapy before and after ovarian cancer diagnosis and ovarian cancer survival. *Int J Cancer* 2006; 119(12): 2907–15.
- MICHAELSON-COHEN R, BELLER U.** Managing menopausal symptoms after gynecological cancer. *Curr Opin Oncol* 2009. Epub ahead of print.
- MØRCH LS, LØKKEGAARD E, ANDREASEN AH, KRÜGER-KJÆR S, LIDEGAARD O.** Hormone therapy and ovarian cancer. *JAMA* 2009; 302(3): 298–305.
- OKTAY K, BUYUK E, VEECK L, ZANINOVIC N, XU K, TAKEUCHI T, OPSAHL M, ROSENWAKS Z.** Embryo development after heterotopic transplantation of cryopreserved ovarian tissue. *Lancet* 2004; 363: 837–40.
- OKTAY K, OKTEM O.** Fertility preservation medicine: a new field in the care of young cancer survivors. *Pediatr Blood Cancer* 2009; 53(2): 267–73. Review.

**REICH M, LESUR A, PERDRIZET-CHEVALLIER C.** Depression, quality of life and breast cancer: a review of the literature. *Breast Cancer Res Treat* 2008; 110(1): 9–17. Epub 2007 Aug 3. Review.

**ROWLAND JH, MEYEROWITZ BE, CRESPI CM, LEEDHAM B, DESMOND K, BELIN TR, GANZ PA.** Addressing intimacy and partner communication after breast cancer: a randomized controlled group intervention. *Breast Cancer Res Treat* 2009. Epub ahead of print.

**SAEWONG S, CHOOBUN T.** Effects of radiotherapy on sexual activity in women with cervical cancer. *J Med Assoc Thai* 2005; 88(Suppl 2): S11–5.

**SERATI M, SALVATORE S, UCCELLA S, LATERZA RM, CROMI A, GHEZZI F, BOLIS P.** Sexual Function after Radical Hysterectomy for Early-Stage Cervical Cancer: Is There a Difference between Laparoscopy and Laparotomy? *J Sex Med* 2009. Epub ahead of print.

**SITRUK-WARE R.** Estrogen therapy during menopause. Practical treatment recommendations. *Drugs* 1990; 39: 203–17.

**TAYLOR C.** Predictors of Sexual Functioning in Ovarian-Cancer Patients. *J Clin Oncol* 2004; 22(5): 881–9.

**TERLOU A, HAGE JJ, VAN BEURDEN M.** Skinning clitorectomy and skin replacement in women with vulvar intra-epithelial neoplasia. *J Plast Reconstr Aesthet Surg* 2009; 62(3): 341–5. Epub 2008 Dec 27.

**VAN ROOIJ IA, BROEKMANS FJ, SCHEFFER GJ, LOOMAN CW, HABBEMA JD, DE JONG FH, FAUSER BJ, THEMEN AP, TE VELDE ER.** Serum antimullerian hormone levels best reflect the reproductive decline with age in normal women with proven fertility: a longitudinal study. *Fertil Steril* 2005; 83: 979–87.

**WRIGHT JD, BUCK AM, SHAH M, BURKE WM, SCHIFF PB, HERZOG TJ.** Safety of ovarian preservation in premenopausal women with endometrial cancer. *J Clin Oncol* 2009; 27(8): 1214–9. Epub 2009 Jan 26.

**WRITING GROUP FOR THE WOMEN'S HEALTH INITIATIVE INVESTIGATORS.** Risks and benefits of estrogen plus progestin in healthy postmenopausal women: principal results from the Women's Health Initiative randomized controlled trial. *JAMA* 2002; 288: 321–33.

**YI JC, SYRJALA KL.** Sexuality after hematopoietic stem cell transplantation. *Cancer J* 2009; 15(1): 57–64.



Dr. med. Juliane Farthmann

Universitäts-Frauenklinik Freiburg  
Hugstetter Straße 55  
79106 Freiburg

Dr. med. Juliane Farthmann, born in 1976 in Hamburg, studied medicine in Gießen and Munich. Since 2005, she is specializing at the Women's Hospital of the Freiburg University.

#### Conflict of interest

The author declares that there is no conflict of interest as defined by the guidelines of the International Committee of Medical Journal Editors (ICMJE; [www.icmje.org](http://www.icmje.org)).

#### Manuscript information

Submitted on: 06.08.2009

Accepted on: 20.08.2009

## Sexual function and fertility preservation in patients with cancer

### Question 1

Which factor has a negative influence on the sexual function of a patient with vulvar carcinoma?

- The radicalness of the operation
- A stable relationship
- The young age of a patient
- Affected lymph nodes
- Histological subtype

### Question 2

In which of the following malignancies is hormone replacement therapy contraindicated?

- Squamous cell carcinoma of the uterine cervix
- Lymphoma
- Hormone receptor-positive breast cancer
- Colon cancer
- Squamous cell carcinoma of the vulva

### Question 3

What type of cancer allows for the administration of local estrogen therapy?

- Ovarian cancer
- Cervical cancer
- Endometrial cancer
- Vulvar cancer
- a-d

### Question 4

What is *not* a reason for impaired fertility secondary to cancer therapy?

- Bilateral adnectomy
- Chemotherapy
- Radiation therapy of the small pelvis
- Ovariopexy prior to radiation therapy
- Hysterectomy

### Question 5

Which intervention for fertility preservation do you recommend to a patient who, due to a hematologic disease, has to initiate chemotherapy within the next few days? The patient currently does not have a partner.

- IVF
- ICSI
- Cryopreservation of ovarian tissue
- In-vitro maturation
- There is no possibility to preserve fertility, as therapy has to be initiated immediately

### Question 6

In the above-mentioned patient, the ovarian reserve is assessed before therapy initiation. Which serum marker is suitable?

- LH (luteinizing hormone)
- FSH (follicle stimulating hormone)
- Estradiol
- AMH (anti-müllerian hormone)
- DHEA (dehydroepiandrosterone)

### Question 7

Pelvic radiation, for example with afterloading applicators, can often cause adhesions of the vaginal mucosa. What is *not* a possibility for preventing or improving this condition?

- Use of lubricating jelly
- Use of vaginal dilators
- Ovariopexy prior to radiation therapy
- Local estrogen therapy
- Bepanthen tampon

### Question 8

Concerning sexual function: what are the possible consequences of an optimal operative and adjuvant therapy of ovarian cancer?

- Decreased ability to reach orgasm because of pelvic and para-aortic lymphadenectomy
- Loss of libido due to a lack of estrogens and androgens after adnectomy
- Fatigue syndrome under chemotherapy
- Lubrication disorders as a consequence of hormone deprivation
- All answers are correct.

### Question 9

An impaired sexual function in patients with breast cancer is associated with...

- ... a negative body image
- ... breast-conserving surgery
- ... hormone receptor-negative carcinoma
- ... a stable relationship
- ... a missing additional psychopathology

### Question 10

What is the differential diagnosis in a patient with sexual dysfunction secondary to cancer therapy?

- Depression
- Chronic fatigue syndrome
- Panic attacks
- Conflicts in personal relationships
- All answers are correct.