

Benign and preinvasive breast lesions

Anke Kleine-Tebbe¹, Aurelia Noske²

¹ DRK Clinics Berlin | Köpenick, Berlin, Germany

² Institute for pathology, Charité Campus Mitte, Charité – University Medical Center Berlin, Germany

Reviewers: Nicolai Maass, Aachen and Mustafa Deryal, Homburg-Saar

Summary

Mammographic screening as well as curative diagnostics have resulted in the increased detection of clinically occult but suspicious breast lesions. Histopathological findings of punch biopsies are classified according to the B-classification (European Working Group on Breast Screening Pathology). The categories B2 (benign) and B5 (malignant) are the most common diagnoses, but the number of detected B3 lesions, i. e. lesions with uncertain malignant potential, is increasing. This B3-category comprises a heterogeneous group of breast tissue alterations, such as atypical intraductal hyperplasia, papillomas and fibroepithelial tumors. Especially the management of atypical intraductal epithelial changes is controversially discussed in literature and is a challenge in the daily clinical routine. Therefore, multidisciplinary conferences have got to be held in order to improve case management.

Introduction

Ever since the introduction of mammography screening, an increasing number of clinically occult lesions are detected that have got to be clarified. Apart from preinvasive changes, also the risk lesions have got to be precisely diagnosed histologically as well as with images in order to make a statement concerning prognosis and therapy. Especially the management of breast lesions with an uncertain malignant potential, also known as B3 lesions, is controversially discussed. This group includes heterogeneous alterations such as papillomas, atypical ductal hyperplasia, flat epithelial atypia and lobular neoplasia, which are associated with a variable risk for malignancy (Dillon et al. 2006). In daily routine, this very often leads to uncertainties concerning further treatment. As these lesions are increasingly detected in percutaneous biopsies, a multidisciplinary case conference is essential. During the course of these preoperative case conferences, the correlation of imaging results with histopathological findings has to be

critically assessed in order to determine further procedures. In the following article, the most frequent benign and preinvasive lesions are depicted and their further management is explained, especially for diagnosed lesions with uncertain malignant potential. Even though current data shows a good correlation of the results of the punch biopsy and the diagnostic excision (Cipolla et al. 2006), premalignant lesions of the breast can be underestimated with histopathological techniques. Diagnostic accuracy depends on the doctor's experience as well as on the number of acquired tissue samples (sufficient sampling). If in imaging only a high risk lesion is manifest, further advanced alterations in the adjacent tissue might have been missed out in the punch biopsy. Sometimes, incomplete removal of the lesion can lead to underestimations. In general, all inconsistent findings (discrepancy between pathological and clinical-radiological finding) by an open biopsy should be further investigated.

B-classification

The B-classification was introduced in the context of mammography screening. Pathomorphological findings of the diagnostic biopsies of mammary glands are classified into one of the five categories and this is then documented in the pathological report. In table 1, the B-classification is outlined.

Table 1: B-classification

Category	Definition
B1a	Non-usable tissue
B1b	Normal tissue
B2	Benign lesion
B3	Indeterminate
B4	Suspicious of malignancy
B5a	Noninvasive carcinoma
B5b	Invasive carcinoma
B5c	Suspicious of invasion
B5d	Other malignancy (e. g. lymphoma)

Classification of benign and preinvasive lesions of the breast

Benign tumors

Fibroadenoma

The fibroadenoma is the most common benign lesion of the breast and is composed of fibrous and glandular tissue. Macroscopically, the 1 to 2 cm big tumor appears as grayish-white, sharply circumscribed nodules. Regressive alterations with hyalinization, calcification and ossification can occur. A fibroadenoma is classified as a BIRADS 3 (Breast Imaging Reporting and Data System) when diagnosed without a biopsy, thus implying a check-up every six months. If the size roughly remains the same after two years, the BIRADS classification changes to 2. The existence of a fibroadenoma does not increase the risk for breast cancer.

Phyllodes tumor

This rare tumor is histologically comparable to the fibroadenoma, but possesses a well-developed stromal component with high cellularity and has bulbous protrusions into the surrounding breast tissue. In contrast to the benign phyllodes tumor, the borderline variance can present with nuclear pleomorphisms and a higher mitotic rate. Because of high risk for recurrence, the malignant phyllodes tumors should be resected with a broad safety margin of at least 1 cm. Depending on tumor size, mastectomy is therefore necessary in many cases. Lymph node metastases are rare, so that axillary lymph node dissection is not required.

Intraductal papilloma

The intraductal papilloma (lactiferous duct papilloma) is either a solitary tumor found within the large (central) lactiferous ducts or multiple found in smaller (peripheral) lactiferous ducts, arising from the epithelial coating of the ducts. Histomorphologically, the intraductal papillary lesion consists of multiple branching papillae, each having a connective tissue septum covered by a double layer epithelium. Intraductal papillary epithelial proliferations can present with a great morphological variety. Apart from the benign epithelial proliferation with ductal epithelial hyperplasia (UDH), cell alterations with malignant potential can be found in the same lesion. The heterogeneity of these lesions has got to be considered, especially when using minimally invasive diagnostic techniques (biopsies). As papillary neoplasia is usually not completely excised, they should subsequently be entirely removed during surgery. However, in most cases a secondary surgery is not necessary. Excision is dispensable if imaging results are easy to evaluate, if the lesion was, with a high probability, removed with the biopsy and if atypical cell morphology was excluded in histology (S3 guidelines of 2008). In benign milk duct papillomas, the risk for malignancies is slightly increased (RR: 2 to 4). In papillomas with cell atypia, the risk for malignancy is increased (RR: 4 to 5).

Hamartoma

The hamartoma is a benign lesion consisting of connective tissue, glandular tissue and lipid tissue in different compositions with a characteristic appearance.

Simple Cyst

A simple cyst is a cavity caused by an extended milk duct or glandular lobule, which is lined by a squamous or apocrine epithelium.

Complex cysts

In contrast to a simple cyst, the ultrasound of a complex cyst shows echoes that are caused by hemorrhage, inflammatory disorders or a thickening of the wall.

Tumor like lesions

Mastopathy

Mastopathy is a complex term that includes a number of degenerative and hyperplastic alterations of the epithelium with a secondary stromal reaction. Concerning pathogenesis, hormonal imbalances are discussed that, via an increased secretion and retention of secretions, leads to cyst formations. Hormone-stimulated proliferation of the ductal and lobular tissue leads to different patterns and degrees of hyperplasia. Local, severe proliferative changes can lead to a diagnosed malignancy, both clinically and in imaging diagnosis. We differentiate between three degrees of severity in mastopathy. Grade I (approximately 70%) with non-proliferative alterations includes a cystic change of the milk ducts, an apocrine epithelial metaplasia as well as a fibrosis due to tissue proliferation in and around the lobules. A mastopathy grade II (approximately 20%) includes benign intraductal epithelial hyperplasia without atypias ("usual ductal hyperplasia", UDH). A special case is sclerosing adenosis, characterized by increased numbers of distorted and compressed acini that can be accompanied by a severe stromal fibrosis. Mastopathy grade III includes the proliferative mastopathy that is connected to atypical ductal (ADH) or lobular (ALH) hyperplasia. Concerning clinical procedures, recommendations range from annual mammographies and surveillance in studies to open biopsies or excisions of the atypical alterations.

Radial scars/complex sclerosing lesion

Radial scars/complex sclerosing lesions are highly suspicious lesions both clinically and radiologically but with only little malignant potential. Histological findings include a nodular structure with proliferating ducts, central fibrosis and elastosis as well as stromal sclerosis. In a conventional histology of a punch biopsy, it can under certain circumstances be difficult to distinguish this lesion from a well-differentiated invasive ductal carcinoma. For differential diagnosis, supplementary immunohistochemical analysis for visualization of the myoepithelium is necessary. This lesion only has a slightly increased malignant potential (RR: < 4). However, in many cases atypical ductal hyperplasia or carcinomas are discerned, whereby implying a diagnostic excision. In a diagnosed radial scar or complex sclerosing lesion, regular senological control examinations are indicated.

Preinvasive lesions and lesions with uncertain malignant potential

Flat epithelial atypia

It is most likely that flat epithelial atypia (FEA according to the WHO, synonyms: columnar cell change with atypia; columnar cell hyperplasia with atypia, Fig.1) is a neoplastic epithelial proliferation (WHO 2003; presumably neoplastic intraductal alteration) that can be classified between UDH and ADH. Histologically, distended acini are visible in the terminal duct lobular units, which are lined with a flat epithelium (one to three cell layers) and displays low grade cytologic atypia. Typically, the acini contain luminal calcifications that may be irregular. It is still unclear whether FEA is an early manifestation of a non-high-grade-DCIS (“ductal carcinoma in situ”), a precursor of lobular neoplasias or a DCIS independent lesion. FEA is often associated with a non-high-grade-DCIS or with a highly differentiated invasive carcinoma (Collins et al. 2007; cut 2003). As the malignant potential of FEA (B3 category) is uncertain, a diagnostic excision for clarification should be performed, depending on the radiological findings.

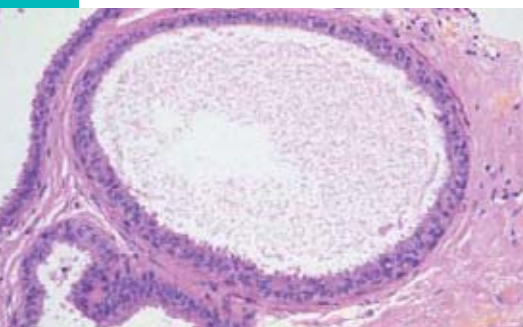


Figure 1: Histological preparation (HE staining) with a flat epithelial atypia

Atypical ductal hyperplasia

Atypical ductal hyperplasia (ADH) is a neoplastic intraductal epithelial hyperplasia with an architectural distortion and minor cytological atypia. The differentiation of ADH from a low grade DCIS may be difficult in the punch biopsy, as, apart from the qualitative, also quantitative characteristics are considered in the diagnosis (diameter up to 2 mm, epithelial hyperplasia restricted to two ducts). The relative risk for developing a carcinoma lies at 4 to 5. Cellular masses of ADH can often be observed at the periphery of invasive or intraductal carcinomas (Wang et al. 2004). This has got to be considered when making use of minimally invasive diagnostic techniques. If an ADH is found in the biopsy sample, the lesion has got to be completely removed. If an ADH is found on the resected edge of a carcinomatous exudate, a secondary excision is not necessary, however, the lesion is of interest to the radiotherapeutic expert.

Ductal carcinoma in situ

The noninvasive ductal carcinoma (DCIS) belongs to the malignant disorders of the breast. An atypical epithelial hyperplasia spreads along the lactiferous ducts and the glandular lobules without invading through the basement membrane. DCIS represents a heterogeneous group in terms of histopathological and prognostic criteria. Depending on the nuclear grade and the central necrosis, three histological types have been defined by the WHO (low, intermediate and high). Due to the associated calcifications, they are visible in mammography; however, the magnitude of the DCIS is very often difficult to determine radiologically. In most cases, the ductal carcinoma spreads segmentally, but also discontinued growth, mainly in higher differentiated types can lead to a multifocal finding in the same segment.

Table 2: DIN-classification

Ductal intraepithelial neoplasia (DIN)	DIN-Terminology
Usual ductal hyperplasia (UDH)	–
Flat epithelial atypia (FEA)	DIN 1A
Atypical ductal hyperplasia (ADH)	DIN 1B
DCIS grade 1 (low grade)	DIN 1C
DCIS grade 2 (intermediate grade)	DIN 2
DCIS grade 3 (high grade)	DIN 3

In the WHO classification of 2003, the traditional terminology of the ductal proliferations (such as UDH, ADH, DCIS) was maintained. If desired, the former classification of the ductal intraepithelial neoplasia (DIN) by Tavassoli (1998) can be applied. In Table 2, the terms of the traditional

terminology and the respective synonyms are subordinated to the 5 degrees of DIN.

Lobular neoplasia

This group contains all atypical epithelial hyperplasia occurring in the lobules or the ductulo-lobular transition zone (terminal duct/lobular unit, TDLU). Lobular neoplasia (LN), synonymous for lobular intraepithelial neoplasia (LIN), contains disorders ranging from atypical lobular hyperplasia (ALH) to the carcinoma lobulare in situ (CLIS). The former WHO terminology (ALH, CLIS) was therefore substituted by the new LN terminology, but is still widely used. A sub-classification of the LIN is being discussed, but not generally recommended by the WHO. It is important to depict the pleiomorphic LIN that is correlated with significant nuclear atypia and associated with comedo necrosis and microcalcifications. This lesion can behave similarly to a DCIS. However, in many cases, LN is a serendipitous finding in the course of biopsies carried out for the diagnostics of other lesions (cellular masses, calcifications). Lobular neoplasia mainly appears as multifocal/multicentric (50%) and bilateral (30%). The relative malignant risk is 6 to 12. Depending on the clinical-radiological finding, a diagnostic excision should be performed if a classical lobular neoplasia is detected in the biopsy material, due to high grade lesions (such as DCIS or an invasive carcinoma) that might

exist in the adjacent tissue. In contrast, the LN of the pleiomorphic or signet-ring cells is classified as a B5 lesion and is therefore an indication for surgery.

Recommendations for the management of benign and preinvasive lesions of the breast

Minimal-invasive diagnostic techniques are important for acquiring tissue material from cell masses, architectural distortions and microcalcifications of the breast (Schulz and Albert 2003). Depending on the radiological findings, a sonographically based punch or vacuum-assisted core biopsy is performed. After resection, the punch cylinder has got to be adequately fixated and processed. In general, up to four histological cuts are stained with HE (hematoxylin and eosin). In the case of microcalcifications, the cylinders have to first undergo preparatory radiography. If there is no correlation to the mammography findings (e.g. missing microcalcifications), further sections are necessary. Frozen section analysis should not be done with the punch biopsy. Apart from the histopathological assessment of the microcalcifications and their correlation to the calcified lesions, the pathological diagnosis also contains information on the B-category. The B-classification contains five categories, which imply various clinical strategies, such as further diagnostics or therapeutic excisions. The categories as well as therapeutic strategies are outlined in Table 3.

Table 3: B-classification of biopsies and management strategies

Classification	Definiton	Recommendations for management	Prevalence
B1	Non-dicipherable or normal tissue	Further diagnostics necessary	Rare
B2	Benign lesion	Diagnotics is completed	Often
B3	<ul style="list-style-type: none"> • Lesions with uncertain malignant potential • Papillary lesions • Radial scar • Classic lobular neoplasia • ADH • FEA • Phyllodes tumor • In some cases uncertain fibroepithelial tumor 	<ul style="list-style-type: none"> • Rarely, another diagnostic biopsy is necessary • Multidisciplinary conference 	Rare
B4	Malignant lesion	Diagnostic biopsy necessary	Rare
B5	<ul style="list-style-type: none"> • DCIS; LN pleiomorphic subtype or with comedo necrosis • Invasive carcinoma • Status of invasion not determinable • Other malignant tumor 	Therapeutic excision necessary	Often

Keywords

Breast, needle core biopsy, B-classification, breast screening, preinvasive lesions

References

- CIPOLLA C, FRICANO S, VIENI S, AMATO C, NAPOLI L, GRACEFFA G, LATTERI S, LATTERI MA.** Validity of needle core biopsy in the histological characterisation of mammary lesions. *Breast* 2006; 15: 76–80.
- COLLINS LC, ACHACOSO NA, NEKHLYUDOV L, FLETCHER SW, HAQUE R, QUESENBERRY CP JR, ALSHAK NS, PULIGANDLA B, BRODSKY GL, SCHNITT SJ, HABEL LA.** Clinical and pathologic features of ductal carcinoma in situ associated with the presence of flat epithelial atypia: an analysis of 543 patients. *Mod Pathol* 2007; 20: 1149–55.
- DILLON MF, McDERMOTT EW, HILL AD, O'DOHERTY A, O'HIGGINS N, QUINN CM.** Predictive value of breast lesions of »uncertain malignant potential« and »suspicious of malignancy« determined by needle core biopsy. *Ann Surg Oncol* 2006; 14: 704–11.
- SCHNITT SJ.** Flat epithelial atypia – classification, pathologic features and clinical significance. *Breast Cancer Res* 2003; 5: 263–68.
- STUFE-3-LEITLINIE.** Brustkrebs-Früherkennung in Deutschland. U.-S. Albert (Hrsg). München: Zuckschwerdt 2008.
- SCHULZ KD, ALBERT US (Hrsg).** Stufe-3-Leitlinie. Brustkrebs-früherkennung in Deutschland. München: Zuckschwerdt 2003; 112.
- TAVASSOLI FA.** Ductal carcinomas in situ: introduction of the concept of ductal intraepithelial neoplasia. *Mod Pathol* 1998; 11: 140–54.
- WANG J, CONSTANTINO JP, TA-CHIU E, WICKERHAM DL, PIKS S, WOLMARK N.** Lower-category benign breast disease and the risk of invasive breast cancer. *J Natl Cancer Inst* 2004; 96: 616–21



Dr. med. Anke Kleine-Tebbe

Leiterin Brustzentrum
DRK Kliniken Berlin | Köpenick
Salvador-Allende-Straße 2–8
12559 Berlin
Germany

Dr. med. Anke Kleine-Tebbe received a thorough gynecological and senological training at the Charité with the focus on gynecologic oncology within the field of gynecology and obstetrics. Over a period of 3 years, she was the director of the interdisciplinary breast centre of the Charité. Because of the excellent cooperation of the participating disciplines (pathology), this article originated together with Dr. Aurelia Noske. Since the 1st of February 2009, Dr. med. Anke Kleine-Tebbe is the director of the certified breast center of the DRK clinics in Berlin.

Conflict of interest

The author declares that there is no conflict of interest as defined by the guidelines of the International Committee of Medical Journal Editors (ICMJE; www.icmje.org).

Manuscript information

Submitted on: 25.01.2009
Accepted on: 17.02.2009

CME-Continuing Medical Education

Benign and preinvasive breast lesions

Question 1

In which of the following lesions, an open excision via percutaneous biopsy after diagnosis is not indicated?

- a. DCIS (ductal carcinoma in situ)
- b. ADH (atypical ductal hyperplasia)
- c. Fibroadenoma
- d. Papillary lesion with atypia
- e. Lobular neoplasia (LN)

Question 2

Which factors lead to the underestimation of risk lesions? Which of the following does *not* apply?

- a. The lesions are only partly removed.
- b. The obtained tissue sample is too small for an exact diagnosis.
- c. Only the high-risk lesion was manifest in imaging diagnosis, but the further evolved lesion in the surrounding tissue was overseen.
- d. Only one punch biopsy was taken.
- e. The patient receives hormonal therapy.

Question 3

The flat epithelial atypia (FEA) corresponds to the following classification in the new DIN terminology:

- a. DIN 3
- b. DIN 1A
- c. DIN 1C
- d. DIN 1B
- e. DIN 2

Question 4

Which factors influence the diagnostic accuracy of a punch biopsy? Which of the following does *not* apply?

- a. The pathologist's experience
- b. Number of tissue samples
- c. Preparation of tissue samples
- d. Experience of the doctor performing the punch biopsy
- e. The patient's age

Question 5

A patient with a newly recognized nodule presents herself. Sonographically, you can see an oval, strictly defined, homogenous tumor. Which procedure is *not* indicated?

- a. Open excision
- b. Histological assurance by sonographically supported punch biopsy
- c. Follow-up after 6 months
- d. Histological confirmation and open extirpation in case of complaints
- e. Histological confirmation via vacuum-assisted core biopsy

Question 6

Which of the following applies to lobular neoplasia (LN)?

- a. Always palpable
- b. In most cases radiologically visible
- c. In histological diagnosis it is never an accidental finding
- d. Diagnosed in punch biopsy, LN III does not represent an indication for an open/diagnostic excision
- e. Adjacent to a LN, higher-grade lesions can be detectable

Question 7

Which procedure is indicated in a papilloma, diagnosed in a punch biopsy?

- a. Operative removal with sentinel lymph node
- b. Complete diagnostic excision
- c. No excision, as papillomas are usually benign
- d. Only excision if atypia is diagnosed in the punch biopsy
- e. Mammography check-up after 6 months

Question 8

Which of the following is *not* a B2 lesion?

- a. Fibroadenoma
- b. Fibrocystic changes
- c. Phylloides tumor
- d. Ductal epithelial hyperplasia (UDH)
- e. Apocrine metaplasia

Question 9

Which of the following statements concerning DCIS applies?

- a. DCIS always progresses into an invasive carcinoma.
- b. DCIS is easily visualized in mammography.
- c. DCIS is only rarely associated with microcalcifications.
- d. DCIS is histologically graded into low grade, intermediate grade and high grade.
- e. Within the B classification, DCIS belongs to the category B3.

Question 10

Which of the following does not apply to lobular neoplasia (LN)?

- a. LN can progress into a ductal invasive carcinoma.
- b. LN can develop into a lobular invasive neoplasia.
- c. LN often appears multilocally.
- d. Higher-grade LN in needle biopsy should be clarified by an open biopsy.
- e. LN III belongs to the B2 category.